

This is the peer reviewed version of the following article:

The COVID-19 Arterial Thromboembolic Complications: From Inflammation to Immunothrombosis Through Antiphospholipid Autoantibodies / Roncati, Luca; Manenti, Antonio; Manco, Gianrocco; Farinetti, Alberto; Mattioli, Anna Vittoria. - In: ANNALS OF VASCULAR SURGERY. - ISSN 0890-5096. - 72:(2021), pp. 216-217. [10.1016/j.avsg.2020.12.006]

*Terms of use:*

The terms and conditions for the reuse of this version of the manuscript are specified in the publishing policy. For all terms of use and more information see the publisher's website.

20/05/2026 08:19



ELSEVIER

**The COVID-19 Arterial Thromboembolic Complications: From Inflammation to Immunothrombosis Through Antiphospholipid Autoantibodies**



Patients with severe SARS-CoV-2 infection are at risk for acute arterial thromboembolic complications: the interesting clinical study by Indes et al. about arterial thromboembolic complications in COVID-19 patients merits some pathophysiological observations.<sup>1</sup> First, the endothelial cells suffer from a hyperinflammatory injury, as proven by the presence of exfoliated circulating elements.<sup>2,3</sup> On this basis, a “lymphocytic endotheliitis” may occur<sup>4</sup>; however, in some circumstances, the vessel condition can seriously complicate toward a “leukocytoclastic vasculitis”,<sup>5</sup> consisting in a neutrophils infiltration inside the tunica media and adventitia, accompanied by fibrinoid necrosis (Fig. 1A and B). In fact, after activation of B lymphocytes into plasma cells, polyclonal immune complexes, mostly IgG but also IgA and IgM, can be deposited at the level of vascular walls, together with C3 complement fraction, unleashing a proper type III hypersensitive reaction.<sup>5,6</sup> This sequence can affect medium to large caliber vessels too, causing an increased risk of thrombosis, in which newly generated platelets play an important co-role. Recruited to repair endothelia, they finalistically implement a mechanism of “covercytosis” against the virions, in consonance with their myeloid lineage inherited from the megakaryocytic progenitors.<sup>7</sup> Meanwhile, the “cytokine storm”, through its key cytokines, the interleukin-6, endowed of megakaryocytopoietic activity, stimulates megakaryocytopoiesis, as testified by the high number of naked-megakaryocyte-nuclei in the bone marrow and lungs of critical COVID-19 patients.<sup>8</sup> Naked-megakaryocyte-nuclei are the expression of megakaryocytes cytoplasm consumption to produce neoplatelets, then released in the microcirculation with prothrombotic effects. This phenomenon can be dramatically amplified by the appearance of antiphospholipid antibodies (lupus anticoagulant, anticardiolipin, anti-β2glycoprotein), able to generate an antiphospholipid syndrome secondary to SARS-CoV-2 infection.<sup>9,10</sup> These autoantibodies bind to phospholipids of platelets membranes, increasing their power of adhesion to endothelia phospholipids and to fibrin filaments (Fig. 1C and D); at the same time, they induce platelets aggregation, reciprocal and with other immune cells, such as neutrophils, monocytes, and lymphocytes. All these lead to the COVID-19

hypercoagulative state characterized by an “abnormal immunothrombosis”. Interestingly, the cascade of events so far illustrated can affect also medium/large-sized vessels, in particular if involved by endothelial dysfunctions, or hemodynamically predisposed for a turbulent blood stream, as along atherosclerotic arteries or in those vessels submitted to previous surgery. Medium-sized arteries can develop a complete thrombotic obstruction (Fig. 1A), while a mural thrombosis can affect large-sized arteries, such as the aorta: the subsequent risk of peripheral embolization, always present, seems reduced by the strong adhesion among the aforementioned hyperactivated platelets.<sup>11</sup> In perspective, this pathological cascade is not the unique possible because endothelial ulcerations and necrotic-inflammatory lesions of the tunica media could produce an “intramural hematoma”, further complicating with an arterial dissection, if not bordered on by the prompt action of procoagulants.<sup>12</sup> Contrariwise, direct connections between “inflammatory” aneurysms and COVID-19 remain uncertain, although the breakdown of collagen structures, cytokines-related, together with occlusive microthromboses of *vasa vasorum* (Fig. 1C) are promoting factors.

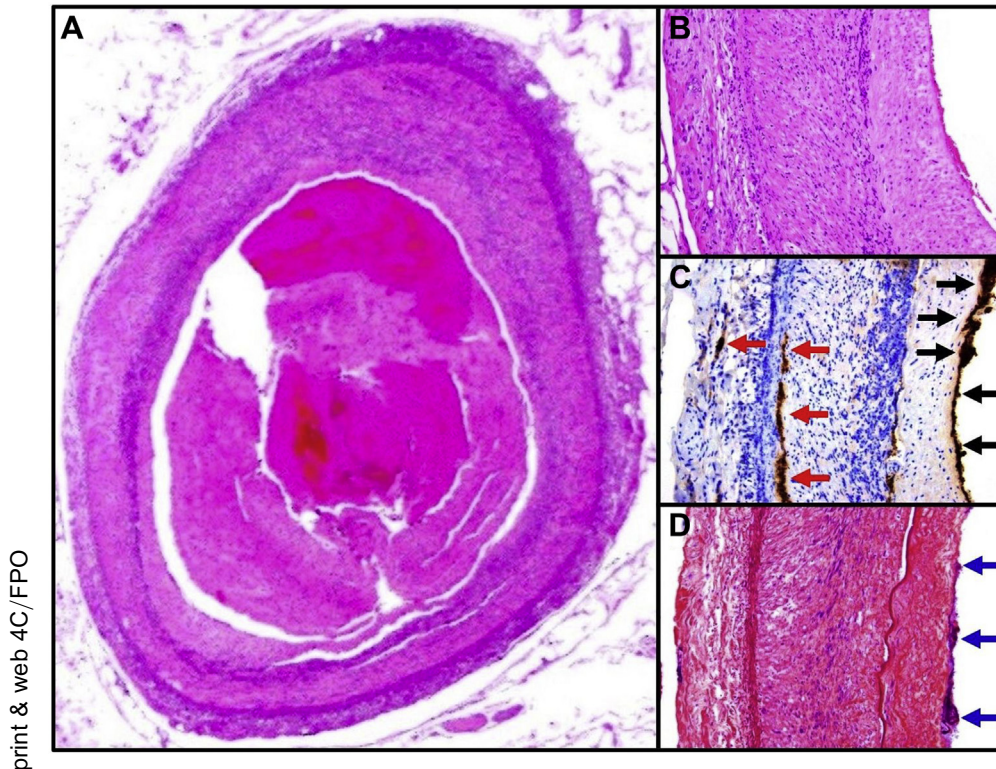
Luca Roncati  
Department of Pathology  
University of Modena and Reggio Emilia  
Modena, Italy

Antonio Manenti  
Gianrocco Manco  
Alberto Farinetti  
Department of Surgery  
University of Modena and Reggio Emilia  
Modena, Italy

Annavittoria Mattioli  
Department of Cardiology  
University of Modena and Reggio Emilia  
Modena, Italy  
E-mail: [antonio.manenti@unimore.it](mailto:antonio.manenti@unimore.it)

REFERENCES

1. Indes JE, Koleilat I, Hatch AN, et al. Early experience with arterial thromboembolic complications in patents with COVID-19. *J Vasc Surg* 2020;. <https://doi.org/10.1016/j.jvs.2020.07.089>.
2. Guervilly C, Burtsey S, Sabatier F, et al. Circulating endothelial cells as a marker of endothelial injury in severe COVID-19. *J Infect Dis* 2020;222:1789–93.



**Fig. 1.** Surgical specimen histopathology from a 72-year-old Italian male patient affected by severe COVID-19: **(A)** complete thrombosis of the medium-sized splenic artery [hematoxylin and eosin, x2.5 objective]; **(B)** neutrophils infiltration accompanied by karyorrhexis inside the tunica media and adventitia, a classical picture of “leukocytoclastic vasculitis”, with a still preserved endothelial layer [hematoxylin and eosin, x10 objective]; **(C)** immunohistochemistry for CD61 reveals platelets interaggregating and adhering to the endothelial cells (*black arrows*), together with occlusive microthrombi of *vasa vasorum* (*red arrows*) [2f2 clone, x10 objective]; **(D)** the platelets aggregates, adhering tenaciously to the endothelium, contain also blue-stained fibrin (*blue arrows*) [phosphotungstic acid hematoxylin, x10 objective].

3. Roncati L, Gallo G, Manenti A, et al. Renin-angiotensin system: the unexpected flaw inside the human immune system revealed by SARS-CoV-2. *Med Hypotheses* 2020;140:109686.
4. Varga Z, Flammer AJ, Steiger P, et al. Endothelial cell infection and endotheliitis in COVID-19. *Lancet* 2020;395:1417–8.
5. Roncati L, Ligabue G, Fabbiani L, et al. Type 3 hypersensitivity in COVID-19 vasculitis. *Clin Immunol* 2020;217:108487.
6. Roncati L, Nasillo V, Lusenti B, et al. Signals of T<sub>H</sub>2 immune response from COVID-19 patients requiring intensive care. *Ann Hematol* 2020;99:1419–20.
7. Manne BK, Denorme F, Middleton EA, et al. Platelet gene expression and function in patients with COVID-19. *Blood* 2020;136:1317–29.
8. Roncati L, Ligabue G, Nasillo V, et al. A proof of evidence supporting abnormal immunothrombosis in severe COVID-19: naked megakaryocyte nuclei increase in the bone marrow and lungs of critically ill patients. *Platelets* 2020;31:1085–9.
9. Bowles L, Platton S, Yartey N, et al. Lupus anticoagulant and abnormal coagulation tests in patients with Covid-19. *N Engl J Med* 2020;383:288–90.
10. Cavalli E, Bramanti A, Ciurleo R, et al. Entangling COVID-19 associated thrombosis into a secondary antiphospholipid antibody syndrome: diagnostic and therapeutic perspectives (review). *Int J Mol Med* 2020;46:903–12.
11. Roncati L, Manenti A, Manco G, et al. Abdominal aortic thrombosis complicating COVID-19 pneumonia. *Ann Vasc Surg* 2020;67:8–9.
12. Patel P, Khandelwal P, Gupta G, et al. COVID-19 and cervical artery dissection - a causative association? *J Stroke Cerebrovasc Dis* 2020;29:105047.