

This is the peer reviewed version of the following article:

Heart failure caused by VGAM: a lesson for diagnosis and treatment from a case and literature review / Spada, C.; Pietrella, E.; Caramaschi, E.; Bergonzini, P.; Berardi, A.; Lucaccioni, L.; Iughetti, L.. - In: THE JOURNAL OF MATERNAL-FETAL & NEONATAL MEDICINE. - ISSN 1476-7058. - 34:14(2021), pp. 2384-2390. [10.1080/14767058.2019.1665013]

*Terms of use:*

The terms and conditions for the reuse of this version of the manuscript are specified in the publishing policy. For all terms of use and more information see the publisher's website.

20/05/2026 12:17

(Article begins on next page)

## Heart failure caused by VGAM: a lesson for diagnosis and treatment from a case and literature review

Caterina Spada, Elisa Pietrella, Elisa Caramaschi, Patrizia Bergonzini, Alberto Berardi, Laura Lucaccioni & Lorenzo Iughetti

To cite this article: Caterina Spada, Elisa Pietrella, Elisa Caramaschi, Patrizia Bergonzini, Alberto Berardi, Laura Lucaccioni & Lorenzo Iughetti (2019): Heart failure caused by VGAM: a lesson for diagnosis and treatment from a case and literature review, The Journal of Maternal-Fetal & Neonatal Medicine, DOI: [10.1080/14767058.2019.1665013](https://doi.org/10.1080/14767058.2019.1665013)

To link to this article: <https://doi.org/10.1080/14767058.2019.1665013>



Accepted author version posted online: 05 Sep 2019.



Submit your article to this journal [↗](#)



View related articles [↗](#)



View Crossmark data [↗](#)

**Title: Heart failure caused by VGAM: a lesson for diagnosis and treatment from a case and literature review.**

**Authors:** Caterina Spada<sup>1</sup>, Elisa Pietrella<sup>1</sup>, Elisa Caramaschi<sup>2</sup>, Patrizia Bergonzini<sup>2</sup>, Alberto Berardi<sup>3</sup>, Laura Lucaccioni<sup>3</sup>, Lorenzo Iughetti<sup>1-2</sup>

**Affiliations:**

1: Post-graduate School of Pediatrics, University of Modena and Reggio Emilia, Italy

2: Pediatric Unit, Department of Medical and Surgical Sciences of Mother, Children and Adults, University of Modena and Reggio Emilia, Italy

3: Neonatal Intensive Care Unit, Department of Medical and Surgical Sciences of the Mother, Children and Adults, University of Modena and Reggio Emilia

**Corresponding Author:** Dr. Laura Lucaccioni, Neonatal Intensive Care Unit, Department of Medical and Surgical Sciences of the Mother, Children and Adults, University of Modena and Reggio Emilia, Via del Pozzo n. 71, 41124 Modena. Tel. 0594223254; Fax: 0594223770; email: [laura.lucaccioni@unimore.it](mailto:laura.lucaccioni@unimore.it). ORCID iD: <https://orcid.org/0000-0003-0288-8990>

Word count: 2539

**Abstract**

We describe the case of a neonate with signs of heart failure. Echocardiography showed a structural normal heart shape with left ventricular dysfunction. At two months of age a vein of Galen arteriovenous malformation was diagnosed through a brain magnetic resonance imaging. Embolization therapy was accomplished and a clinical and neurological follow up was started. This clinical case highlights how important it is considering an intracranial cause in the differential diagnosis of neonatal congestive heart failure.

We performed a narrative mini-review of the literature about treatments and outcome of this malformation in association to congestive heart failure, to point out how complex the diagnosis of vein of Galen aneurysmal malformation may be and how an early diagnosis is important for its management.

### **Keywords**

Neonate, vein of Galen malformation, cardiac failure, endovascular treatment

### **Introduction**

Vein of Galen aneurysmal malformation (VGAM) is a rare cause of congestive heart failure during the first months of life leading to a high mortality rate [1]. VGAM should be suspected when a neonatal idiopathic heart failure occurs. The bregmatic fontanel auscultation is a simple clinical screening and can reveal a pathognomonic murmur in presence of VGAM, but it is not routinely performed [2]. We describe the clinical case of a newborn with heart failure as a first sign of VGAM, whose diagnosis has been delayed. Moreover, we have performed a narrative

mini-review of the literature about the age of presentation, the treatment and the clinical outcome of the malformation, to point out how complex the diagnosis is and when the clinical suspicion should be considered.

### **Case Report**

Male, born at term by vaginal delivery to an uncomplicated pregnancy. Apgar scores was 9 at 1' and 10 at 5'. At birth, it was noticed a small left palpebral swelling, considered as a delivery trauma. At the age of 20 days of life he was referred for failure to thrive: a gallop rhythm was found at the cardiac examination and an echocardiography revealed a left ventricular dysfunction. The newborn was referred to the closer Pediatric Cardiology Centre, where signs of left ventricular dysfunction were confirmed and a pulmonary congestion with pulmonary hypertension were noticed. Medical treatment for heart failure was started with loop diuretic and ACE inhibitor, adding subsequently a beta-blocker, with progressive clinical improvement. In absence of structural causes of heart failure, metabolic investigations were performed with normal results. The patient was discharged after 8 days with a diagnosis of "initial signs of cardiac failure in transient left ventricular dysfunction and pulmonary hypertension" in therapy with furosemide, carvedilol, potassium canreonato. At 2 months of age the infant was referred to our attention for the persistence of the left supraorbital swelling, since birth and the increase of head circumference. The association of supraorbital swelling and heart failure of unknown origin, led us to perform an elective neuro-radiological investigation. The brain magnetic resonance imaging (MRI) showed a complex vascular malformation compatible with VGAM (Figure 1a). In the left supraorbital region, an ectatic venous structure was observed. Furthermore, an external hydrocephalus was documented. This was as a result of systemic venous hypertension which caused fluid cerebrospinal malabsorption.

Consequently, he underwent an uncomplicated neurosurgical endovascular embolization (Figure 1b). The patient was discharged after about 15 days of hospitalization, in good clinical conditions with a diagnosis of VGAM.

During the neuroradiology and neurosurgical follow up, a second embolization treatment was needed after about 4 months. There were no complications. CGH-array and mutational analysis

of the RASA1 gene (usually associated with arteriovenous malformations) did not identify causative mutations.

Cardiac serial controls documented a progressive normalization of the left ventricular functionality, allowing the progressive decalage of the medical therapy, stopped at about 9 months of life.

## **Narrative mini-review**

### ***Methods***

The literature research was conducted independently by 2 investigators (CS and EP) using the PubMed CENTRAL databases. The following combinations of key words were used: (vein of Galen malformations OR arteriovenous aneurysms of the vein of Galen OR vein of Galen aneurysm malformations OR aneurysms of the vein of Galen) AND (endovascular embolism OR endovascular therapy) AND (heart failure). The research was limited to papers published in English from March 1988 till September 2018. The reference lists of retrieved studies have also been reviewed to identify studies that may have not been spotted by the search strategy.

### ***Inclusion Criteria***

Papers included in our analysis were required to meet all of the following criteria: 1) Reports of patients with VGAM 2) Reports of patients undergoing endovascular embolization 3) Reports focused primarily on the age at diagnosis, the onset of treatment and the outcome of VGAM 4) Reports describing at least 3 clinical cases of VGAM.

### ***Data Extraction***

39 Pubmed CENTRAL studies were independently assessed by 2 investigators (CS and EP) using a standardized data abstraction form (Figure 2). We excluded all the studies with insufficient information, possible biases and contradictions, inconsistent or arbitrary conclusions. We finally analyzed 8 papers corresponding to all the criteria selected. Two articles based on the same population were regarded as one [3,4]. The information that was extracted from each article is shown in Table 1 [3-10].

## **Results and Discussion**

### ***Classification of VGAM***

VGAM has been classified in several different ways. The Lasjaunias and the Yasargil classifications are generally the most used [11]. The Lasjaunias classification distinguishes malformations in choroidal or mural types, depending on the number and origin of feeding arteries. The Yasargil classification divides the malformations in 4 types; Type I, II and III are characterized by a fistulous communication in the vein of Galen, while in type IV there is a parenchymal arteriovenous malformation that drains into the vein of Galen [11]. Our patient had an aneurysmal dilation of the vein of Galen shunting from an adjacent thalamic AVM, which can be classified as type IVa by the classification criteria of Yasargil et al. and as “mixed type” for the Lasjanunias criteria. In six articles the Lasjaunias’ classification was used [3,4,7-10], in other two it wasn’t specified [5,6]. Chow et al. described a prevalence of mixed-type VGAM (31.7%), followed by mural-type (29.3%) and choroidal type (26.8%) [3]. Hassan noted a prevalence of mural types, while Heuer, Meila and Rodesh a higher percentage of choroidal types [7-10].

### ***Physiopathology of VGAM***

During the fetal life, high-output cardiac failure doesn’t occur. Low vascular resistance in the cerebral arteriovenous malformation is balanced by the low resistance of the utero-placental unit. After birth the exclusion of the low resistance placental circulation with the consequent rise in systemic vascular resistance, increases blood flow through the cerebral arteriovenous fistulas (in severe cases up to 80% of cardiac output). This results in an initial decrease of the systemic circulation, followed by a significant increase in cardiac output and blood volume, in order to maintain a systemic perfusion. Raising venous return to the right heart creates a right-to-left shunt through a patent foramen ovale. Increased blood flow through pulmonary vessels leads to pulmonary hypertension, which ultimately leads to a right-to-left shunt through the ductus arteriosus. The ductus arteriosus which remains patent as a pressure of the pulmonary circulation exceeds the one of the systemic circulation [7].

The size of the fistulas determines the amount of arteriovenous shunt and consequently the time needed for the development of cardiac failure. Due to a low vascular resistance of the head, the majority of the left ventricular output is directed toward the cerebral system. During the diastole, the systemic perfusion is further reduced by circulatory “steal” to the vein of Galen aneurysmal

malformation, which produces the characteristic reversed diastolic flow in the descending aorta. The coronary blood flow is reduced by this diastolic steal phenomenon and, this combined with increased ventricular pressures, can lead to a reduced myocardial perfusion or even an ischemia, further compromising cardiac function [12]. These 2 mechanisms (relative hypovolemia and cardiac dysfunction) lead to reduced systemic blood flow, severe lactic acidosis, potentially ischemic multiple organ failure and persistent pulmonary hypertension [13].

Chevret et al. analyzed 24 newborns with VGAM and cardiac failure requiring mechanical ventilation. The existence of pulmonary artery hypertension, cardiogenic shock, patent ductus arteriosus with a significant right-to-left shunt and a descending aortic diastolic reverse flow before embolization was associated to a poor prognosis [5]. In our case, despite the delayed diagnosis of VGAM, the achievement of a good medical control of the congestive heart failure (CHF) could have minimized the progression of complications.

### ***Clinical presentation of VGAM***

Patients with VGAM most commonly present with cardiac and neurologic complications. The clinical presentation depends on the age of onset.

According to age, we grouped the 74 patients with VGAM associated to heart failure in 3 categories from six of the studies analyzed [5-10]. For one article this analysis was not applicable [3]. The largest group included neonates (<1 month) that generally (in nearly 90% of cases) showed high-output cardiac failure, pulmonary hypertension, and in worst cases, multi-organ failure. The second group included infants ( $\geq 1$  month to < 2 years) who commonly present a hydrocephalus, seizures, or neurocognitive delay (10% of cases). Older children ( $\geq 2$  years) and adults' usual manifestations are headaches or intracranial hemorrhage (Table 1). In one study, at admission all babies presented clinical signs of severe cardiac failure with tachycardia, tachypnea, and hepatomegaly. The majority had a cervical "dancing" carotid pulse and distended jugular veins. An echocardiogram showed in every patient increased venous return and right heart overload [5].

Another study described the association of VGAM and congestive heart failure in 61% of the cases, while there was 65.9% with hydrocephalus, 34.1% with intracranial hemorrhage and 29.3% with seizures [3].

The symptoms of our patient started at 20 days of life with heart failure and pulmonary hypertension. Our patient developed also hydrocephalus, as reported in infants' group, probably due to a delayed diagnosis (at 2 months). When heart failure occurs beyond the neonatal period, it is usually mild or moderate and may be controlled by medical treatment [14]. The clinical picture is dominated by suggestive signs of a congenital cardiac disease such as cyanosis, compromised peripheral pulses, and a cardiac murmur. Often cyanosis is a manifestation of persistent pulmonary hypertension of the newborn, with signs of right-to-left arterial shunt at the ductal level. These are common clinical presentations of heart failure and not specific for the VGAM association. A pathognomonic sign is the presence of a continuous murmur heard on the anterior fontanel [2]. This screening should be routinely performed in cases of heart failure of unknown origin.

### ***Imaging characteristics of VGAM and its complications***

Prenatal diagnosis, fetal MRI and echocardiography give the opportunity to schedule the delivery in a tertiary care center, where immediate care can be provided by a multidisciplinary team. An early diagnosis is very crucial in the management of VGAM [8,11]. When VGAM is suspected, a cranial ultrasound (US) as soon as possible after birth, can help identifying the lesion [12]. CT and MRI give a clear demonstration of the intracranial arteriovenous malformation. Cerebral angiography is the gold standard imaging modality to provide an accurate anatomical definition of all the vessels refurnishing the fistula, and should be performed as part of the planned endovascular intervention, more than for diagnostic purposes [14]. In the Chow et al. analysis, postnatal CT was the most commonly used diagnostic tool, followed by postnatal MRI, fetal ultrasound, postnatal ultrasound and angiography [3]. In the Chevret et al. population three babies received the diagnosis of VGAM in utero by fetal ultrasound at the third trimester and two of them also underwent a fetal MRI [5].

In our case, the diagnosis was made by a brain MRI at two months of age, for the persistence of the left supraorbital swelling associated to heart failure of unknown origin.

### ***Treatment and outcome of VGAM***

The treatment of VGAM can only be performed after cardiovascular stabilization. This is achieved by reducing systemic and pulmonary vascular resistance and improving the non-cerebral systemic output and the myocardial function [14].

The main method of treatment of VGAM is the endovascular embolization. This technique occludes the arteriovenous shunt and the pathological arteries and aneurysmal veins are disconnected from the circulation [5]. Heuer et al. underlined that often the immediate aim of endovascular treatment is to stabilize the child until the he will be able to tolerate additional procedures [8].

Of the 7 studies analyzed, 5 reported data regarding the extent of the embolization. Complete occlusion was achieved in 53% of the cases; partial occlusion was attained in the remaining. In 4 studies it was reported at the age of the first endovascular session, with a mild prevalence of the neonatal period (51.2%of cases) (Table 1).

Endovascular embolization decreased the mortality for VGAM at 10-16% of all the treated patients. The age of treatment is crucial for the mortality rate [15]. We analyzed the overall 38% mortality rate, 19% before and 19% after intervention (Table 1). A higher mortality rate is described in Chevret et al. population: six patients were not embolized because of impossible technical challenges. Three patients had severe cardiogenic shocks with hypotension and aortic reverse flow and three patients evidenced severe brain damage with subsequent death. Six more patients died after the first embolization because of multiple organ failure and intractable cardiac failure [5].

The timing of intervention is also critical. Lasjaunias and colleagues described the optimal therapeutic window for initiating the endovascular treatment at around 5 months of age. This was needed to maximize the efficacy of the intervention and minimize the risk of delay in cerebral maturation [16]. If treatment is deferred longer, correction of hydrocephalus may not be possible by treating the VGAM and neurologic and cognitive sequelae can become permanent [14].

After the first intervention, subsequent treatments are performed using a routine interval of 6 to 8 weeks or a shorter interval of 4 weeks for more complex lesions. Emergency embolization is sometimes necessary with neonates. The primary goal is to decrease flow through the VGAM to normalize systemic physiology. In addition, reducing flow through a VGAM in a neonate can help recreate conditions to allow maturation of the cerebral venous system.

Our patient underwent two embolizations at 2 and 6 months of age, the first when receiving diagnosis and another one during the neurological follow-up.

A good outcome is expected when the treatment is performed before the occurrence of a significant brain injury.

To describe the patients' outcome we used a score graded on a 4-point scale according to Jones et al., ranging from 1 to 4 [17]. Clinical outcome was classified as good for scores between 4 and 3 (neurologically normal and mild developmental delay), and poor for scores of 2 and 1 (moderate and severe developmental delay). Cases of death were excluded. However, not every study provided scores to assess grading. Therefore, we classified the clinical outcome as good or poor according to the clinical symptoms of patients if a score was lacking. Patient clinical outcome was analyzed in 7 studies. A poor outcome was observed in 40% of patient (Table 1). In Chevret et al. study, the worst outcomes described were neurodevelopmental delay with axial hypotonia, moderate neurologic delay with seizures, severe disability in the sensory and communication domain, including seizures, without having the opportunity to attend regular school. All of them had neuromotor sequelae [5]. Heuer et al. described a poor outcome in two patients, one with severe mental delay and one with hemiparesis, moderate mental delay and controlled epilepsy [8].

## **Conclusion**

Vein of Galen aneurysmal malformation is a rare condition, with an incidence of 1% of the arteriovenous vascular anomalies [18]. Because of the high mortality rate, it is important to minimize any diagnostic delay and consider VGAM in the differential diagnosis of neonatal congestive heart failure [19]. The auscultation of the fontanel is a simple screening to achieve this target.

Initial treatment is targeted at improving non-cerebral systemic circulation and reduction in pulmonary vascular resistance. When circulatory stabilization can be achieved, endovascular treatment of the arteriovenous malformation is the preferred modality. A subsequent endovascular interventions is often needed to reach complete occlusion.

**Acknowledgements:** Not Applicable.

**Declaration of interest statement:** The authors report no conflict of interest.

## References

- [1] Berenstein A, Fifi JT, Niimi Y, et al. Vein of Galen malformations in neonates: new management paradigms for improving outcomes. *Neurosurgery*. 2012 May;70(5):1207-13; discussion 1213-4.
- [2] O'Donnabhain D, Duff DF. Aneurysms of the vein of Galen. *Arch Dis Child*. 1989;64(11):1612–1617.
- [3] Chow ML, Cooke DL, Fullerton HJ, et al. Radiological and clinical features of vein of Galen malformations. *J Neurointerv Surg*. 2015; 7(6):443-8.
- [4] Fullerton HJ, Aminoff AR, Ferriero DM, et al. Neurodevelopmental outcome after endovascular treatment of vein of Galen malformations. *Neurology*. 2003; 61(10):1386-90.
- [5] Chevret L, Durand P, Alvarez H, et al. Severe cardiac failure in newborns with VGAM. Prognosis significance of hemodynamic parameters in neonates presenting with severe heart failure owing to vein of Galen arteriovenous malformation. *Intensive Care Med*. 2002; 28(8):1126-30.
- [6] Wong FY, Mitchell PJ, Tress BM, et al. Hemodynamic disturbances associated with endovascular embolization in newborn infants with vein of Galen malformation. *J Perinatol*. 2006; 26(5):273-8.
- [7] Hassan T, Nassar M, Elghandour M. Vein of Galen aneurysms: presentation and endovascular management. *Pediatr Neurosurg*. 2010; 46(6):427-34.
- [8] Heuer GG, Gabel B, Beslow LA, et al. Diagnosis and treatment of vein of Galen aneurysmal malformations. *Childs Nerv Syst*. 2010; 26(7):879-87.
- [9] Meila D, Hannak R, Feldkamp A, et al. Vein of Galen aneurysmal malformation: combined transvenous and transarterial method using a "kissing microcatheter technique". *Neuroradiology*. 2012; 54(1):51-9.
- [10] Rodesch G, Hui F, Alvarez H, et al. Prognosis of antenatally diagnosed vein of Galen aneurysmal malformations. *Childs Nerv Syst*. 1994; 10(2):79-83.
- [11] Puvabanditsin S, Mehta R, Palomares K, et al. Vein of Galen malformation in a neonate: A case report and review of endovascular management. *World J Clin Pediatr*. 2017 Feb 8;6(1):103-109.

- [12]De Beritto T, Khan OA, Hageman JR, et al. Vein of Galen arteriovenous malformation in a neonate. *Pediatric Annals* 2015; 44(10): e243-e24.
- [13]Mathews AZ, Ibhanebhor S, Richens T, et al. Heart failure in the new born; vein of Galen aneurysmal malformation. *BMJ Case Rep.* 2013 Jan 23;2013.
- [14]Recinos PF, Rahmathulla G, Pearl M, et al. Vein of Galen malformations: epidemiology, clinical presentations, management. *Neurosurg Clin N Am.* 2012; 23(1):165-77.
- [15]Yan J, Wen J, Gopaul R, et al. Outcome and complications of endovascular embolization for vein of Galen malformations: a systematic review and meta-analysis. *J Neurosurg.* 2015 Oct;123(4):872-90.
- [16]Lasjaunias PL, Chng SM, Sachet M, et al. The management of vein of Galen aneurysmal malformations. *Neurosurgery* 2006;59:S184.
- [17]Jones BV, Ball WS, Tomsick TA, et al. Vein of Galen aneurysmal malformation: diagnosis and treatment of 13 children with extended clinical follow-up. *AJNR Am J Neuroradiol* 23:1717–1724, 2002.
- [18]Raybaud CA, Strother CM, Hald JK. Aneurysms of the vein of Galen: embryonic considerations and anatomical features relating to the pathogenesis of the malformation. *Neuroradiology.* 1989;31:109–128.
- [19]De Rosa G, De Carolis MP, Tempera A, et al. Outcome of Neonates with Vein of Galen Malformation Presenting with Severe Heart Failure: A Case Series. *Am J Perinatol.* 2019;36:169-175.

**Table 1.** Age at diagnosis in the studies included, age at treatment, mortality rate and outcome

Author and year			Age at VGAM diagnosis n =101			Age at CHF diagnosis n=74			Endovascular treatment n=62					Outcome n=50				
			Neonate	Infant	Child or Adult	Neonate	Infant	Child or Adult	Total	After intervention	Before intervention	Poor	Good					
Chevrefrance 2002	96	24	24	0	0	24	0	0	18	NA	NA	NA	NA	12	6	6	9	3
Chow, USA 2014	41	25	NA	NA	NA	NA	NA	NA	NA	NA	NA	NA	NA	NA	NA	NA	NA	NA
Hassan,Egypt 2010	13	4	0	7	6	0	4	0	3	NA	NA	NA	0	1	0	1	0	3
Heuer, USA 2010	13	7	9	3	1	7	0	0	6	6	0	0	3	3	2	1	2	2
MeilaGermany 2011	28	14	11	3	0	8	6	0	14	8	6	0	13	1	1	0	4	9
RodeschFrance 1994	18	16	18	0	0	16	0	0	12	0	12	0	7	4	0	4	4	8
WongAustralia 2006	9	9	9	0	0	9	0	0	9	7	2	0	6	3	3	0	1	5
<b>Freq. (%)</b>			(71,3)	(22,8)	(6,9)	(86,5)	(13,5)	(0)	(51,2)	(48,8)	(0)	(70,7)	(38)	(19)	(19)	(40)	(60)	

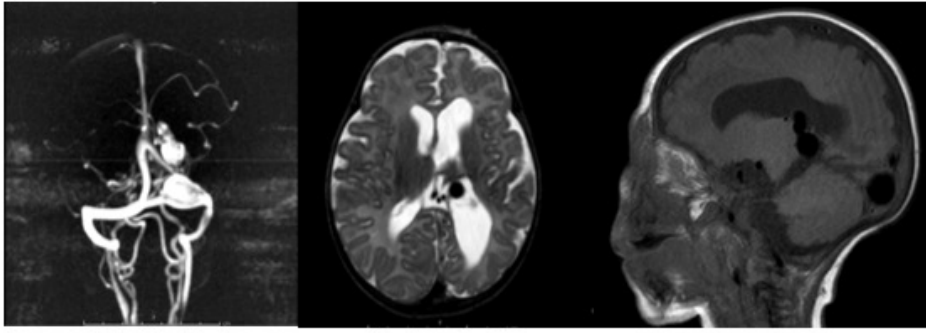
Legend NA= not available.

## Figures captions

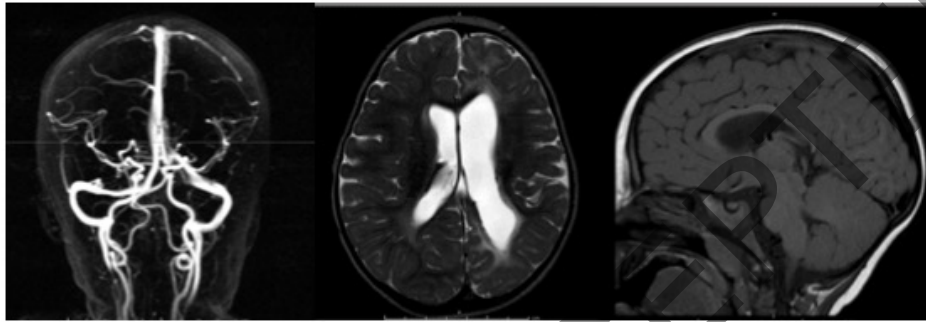
**Figure 1a Brain MRI of our case at diagnosis:** The MRI image shows a complex vascular malformation characterized by ectatic venous structures with aneurysmal dilatation in direct communication with the posterior cerebral and choroidal arteries in the region of left lateral ventricle. In the left occipito parietal hemisphere a ulegyric aspect of cerebral gyrus and ex-vacuous dilatation of the left lateral ventricle was also noticed. **Figure 1b Brain MRI after two embolization treatments:** In this MRI the ectatic venous structures are not recognisable. There is persistence of the ex-vacuous dilatation on the left lateral ventricle.

**Figure 2.** Flowchart of review process and selection of the studies

JUST ACCEPTED

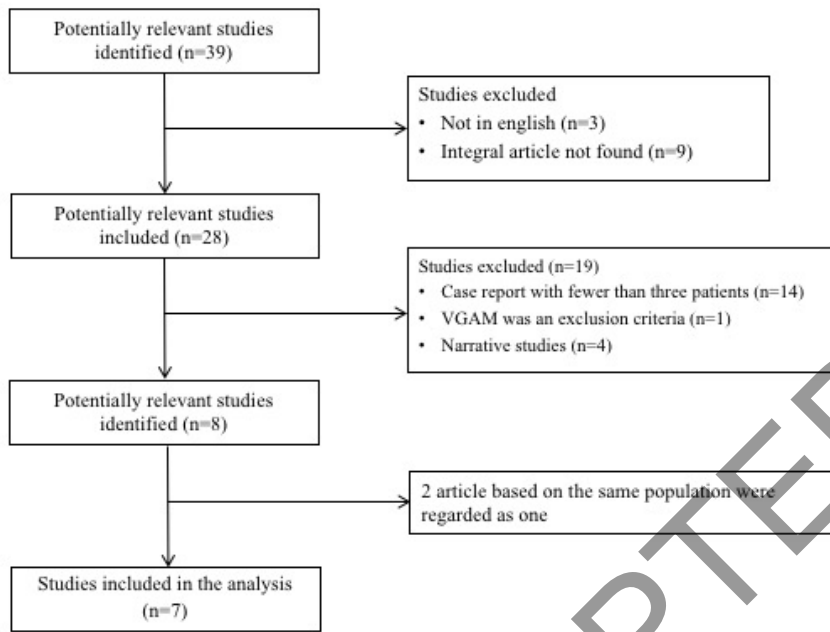


1a



1b

JUST ACCEPTED



JUST ACCEPTED