

This is the peer reviewed version of the following article:

Permanent implants for lip augmentation: Results from a retrospective study and presentation of tips and tricks / Guida, S., Mandel, V.D., Farnetani, F., Manola, C.M., Rubino, G., Ruzzu, S., Pellacani, G., Longo, C., Urtis, G.G.. - In: JOURNAL OF PLASTIC, RECONSTRUCTIVE & AESTHETIC SURGERY. - ISSN 1748-6815. - 70:5(2017), pp. 699-704. [10.1016/j.bjps.2017.02.005]

*Terms of use:*

The terms and conditions for the reuse of this version of the manuscript are specified in the publishing policy. For all terms of use and more information see the publisher's website.


08/06/2026 09:22

(Article begins on next page)

# Accepted Manuscript

Permanent Implants for Lip Augmentation: results from a retrospective study and presentation of tips and tricks

S. Guida, MD, V.D. Mandel, MD, F. Farnetani, MD, C.M. Manola, MD, G. Rubino, MD, S. Ruzzu, MD, G. Pellacani, MD, C. Longo, MD, PhD, G.G. Urtis, MD



PII: S1748-6815(17)30083-9

DOI: [10.1016/j.bjps.2017.02.005](https://doi.org/10.1016/j.bjps.2017.02.005)

Reference: PRAS 5243

To appear in: *Journal of Plastic, Reconstructive & Aesthetic Surgery*

Received Date: 2 December 2016

Revised Date: 16 January 2017

Accepted Date: 17 February 2017

Please cite this article as: Guida S, Mandel V, Farnetani F, Manola C, Rubino G, Ruzzu S, Pellacani G, Longo C, Urtis G, Permanent Implants for Lip Augmentation: results from a retrospective study and presentation of tips and tricks, *British Journal of Plastic Surgery* (2017), doi: 10.1016/j.bjps.2017.02.005.

This is a PDF file of an unedited manuscript that has been accepted for publication. As a service to our customers we are providing this early version of the manuscript. The manuscript will undergo copyediting, typesetting, and review of the resulting proof before it is published in its final form. Please note that during the production process errors may be discovered which could affect the content, and all legal disclaimers that apply to the journal pertain.

## **Permanent Implants for Lip Augmentation: results from a retrospective study and presentation of tips and tricks**

**Running head:** Lip augmentation with prosthesis

**Authors:**

Guida S<sup>1</sup>, MD; Mandel VD<sup>1</sup>, MD; Farnetani F<sup>1</sup>, MD; Manola CM<sup>2</sup>, MD; Rubino G<sup>3</sup>, MD; Ruzzu S<sup>2</sup>, MD; Pellacani G<sup>1</sup>, MD; Longo C<sup>4</sup>, MD, PhD\*; Urtis GG<sup>2</sup>, MD\*.

1. Dermatology Unit, University of Modena and Reggio Emilia, Modena, Italy
2. Istituto DermoEstetico (IDE), Milan, Italy
3. Department of Maxillofacial Surgery, Galeazzi Hospital, Milan, Italy
4. Skin Cancer Unit, Arcispedale S. Maria Nuova-IRCCS, Reggio Emilia, Italy

\*Equally contributed

Stefania Guida

Dermatology Unit, University of Modena and Reggio Emilia, Modena, Italy

Victor Desmond Mandel

Dermatology Unit, University of Modena and Reggio Emilia, Modena, Italy

Farnetani Francesca

Dermatology Unit, University of Modena and Reggio Emilia, Modena, Italy

Carmelo Mirko Manola

Istituto DermoEstetico (IDE), Milan, Italy

Rubino Giuseppe

Department of Maxillofacial Surgery, Galeazzi Hospital, Milan, Italy

Ruzzu Simonetta

Istituto DermoEstetico (IDE), Milan, Italy

Giovanni Pellacani

Dermatology Unit, University of Modena and Reggio Emilia, Modena, Italy

Caterina Longo

Skin Cancer Unit, Arcispedale S. Maria Nuova-IRCCS, Reggio Emilia, Italy

Giacomo Giovanni Urtis

Istituto DermoEstetico (IDE), Milan, Italy

**Corresponding author:**

Stefania Guida

Department of Dermatology, University of Modena and Reggio Emilia,  
Via del Pozzo 71, 41124 Modena, Italy.

E-mail: stefania.guida@alice.it

**Abstract (244)****Background**

The request for lip augmentation is increasing due to expanding media exposure and consumer needs. Temporary effects can be obtained with several techniques but a recent procedure, consisting of lip prosthesis implantation, offering a permanent result, is emerging. Accordingly, the implant of solid lip prosthesis represents an innovation in the field of aesthetic medicine and surgery.

**Methods**

100 women with atrophic or hypoplastic lips were treated with lip implants. The treatment was performed in a single session and controls were scheduled at fixed time intervals. Standard digital photo was used for measurement and analysis.

Data concerning patient's satisfaction and complications of the technique were collected and analyzed. Variations to the original technique were also discussed.

**Results**

Patient's evaluation revealed a permanent and natural result without discomfort for the patient and/or the partner was reached with the implant of silicone prosthesis in the upper and/or lower lip. Swelling, bruising and malpositions were the most frequent adverse events. A case of severe oedema was reported. Practical tricks acquired through experience were discussed in order to prevent complications.

**Conclusions**

One of the most widespread methods for lip remodeling is represented by hyaluronic acid injections. Nevertheless, hyaluronic acid has a variable duration and it is not always the first choice. This context allowed the development of other techniques among which the implant of silicone prosthesis. Advantages of these prosthesis are: safety, definitive result and reversibility considering the possibility to remove the implanted prosthesis in case of request.

**Keywords:**

Lip augmentation, silicone prosthesis, filling procedures, permanent lips

**Number of figures:** 5.

**Number of tables:** none.

**Number of words:** 2742.

**Funding:** none.

**Conflict of interest:** none.

ACCEPTED MANUSCRIPT

## INTRODUCTION

With age, the lips lose their youthful pout and effacement, while the lip commissures point downward, atrophy sets in, and lip fullness disappears.

Currently available commercial techniques can be grouped in filling and non-filling procedures.<sup>1,2</sup>

After the era of liquid injectable silicone, other techniques providing a temporary lip remodeling were introduced, like hyaluronic acid injections or autologous fat.<sup>1</sup>

Numerous fillers have been effective for lip rejuvenation, but all these products are temporary, expensive, and require fluid or tissue in-growth for their effect. However, these fillers offer patients an important nonsurgical option because they need minimal anesthesia and can provide a high degree of patient satisfaction.<sup>1,2</sup>

Autologous fat is an expensive treatment that has been used as injectable filler, but the results are temporary and also marred by evident imperfections.<sup>1</sup>

Lip augmentation is a common way of reversing the “deflated” appearance due to inversion and soft-tissue atrophy.<sup>3</sup> Nowadays a plethora of lip augmentation approaches exist. To satisfy customers’ desires, they should adapt to the shape of the lips, be natural in appearance and feel, easily reversible, replaceable, and adjustable such as filler. Moreover, they should preserve labial architecture and contours, therefore avoiding the so-called “sausage” lips.<sup>4</sup>

To reach these goals, treatments should consist of increasing vermilion height, enhancing pout, effacing lines and wrinkles, adding volume uniformly and masking excess visible dentition.<sup>3,4</sup>

Accordingly, to correct unaesthetic gummy smile, surgical lip positioning can be planned to limit the retraction of the elevator smile muscles (zygomaticus minor, levator anguli oris, orbicularis oris and levator labii superioris) which creates narrow vestibule and restricted muscle pull reducing gingival display during smiling. Furthermore, lower lip augmentation can help not only make someone look youthful at almost any age and still look natural but also obscuring the lower teeth visibility.

It is very important that the technique should be easy to perform, reproducible, brief and well-tolerated with fast recovery.<sup>3</sup>

Implant of solid lip prosthesis represents an innovation in the field of aesthetic medicine and surgery.<sup>1,2</sup> In particular, permanent implants (PermaLip™, SurgiSil LLP, Plano, Texas, USA) represent a solution to obtain a permanent lip augmentation and they are available in three diameters (3, 4 and 5 mm) and variable lengths (55, 60 and 65 mm) to fit any adult lip.<sup>4</sup> It is composed by a soft, unbreakable, solid silicone elastomer characterized by a smooth surface that can be removed at any time following patient's desire.

Here we present our experience with silicon prosthesis, including patient evaluation, complications and tips and tricks gained through daily practice experience.

## **MATERIALS AND METHODS**

This is a retrospective study including 100 women, asking for permanent lip augmentation, treated in the context of private practice with silicone prosthesis between 2013 and 2015. Among these patients, 85 were previously treated with hyaluronic acid fillers.

The principles outlined in the Declaration of Helsinki have been followed.

Inclusion criteria were: people from 18 years old, with hypoplastic lips, with a long philtrum or desiring lip augmentation, asking for a permanent result.

Exclusion criteria: severe diseases like autoimmune and coagulation diseases, pregnancy and nursing.

### Operative procedure

The treatment was performed as previously described by Raphael *et al.*<sup>4</sup> First of all, an infraorbital and mental nerve block was performed and after that a local anesthesia was introduced directly into the lips below the sub-mucosa. Then, bilateral commissure incisions with scissors were made and a plane was dissected just below the sub-mucosa (Figure 1a). Afterwards, a tendon passer was placed into the upper and lower lips, along the course of the moist and dry vermilion junction. The implants were then pulled across the lips into the proper position (Figure 1b). In almost all the patients we inserted the 4-mm-wide model, while the 3-mm size was selected only for few patients

with very small lips. Instead, we didn't use the 5-mm-wide model, which is mainly indicated for big lips or in removal and replacements when patients returned to request an additional volume. The implants are all made of silastic and taper at the ends. Finally, bimanual palpation was performed to confirm correct position and avoid revisions. Bilateral commissure incisions were closed with 4-0 chromic sutures.

After treatment, pain medicines were prescribed to all patients and cephalexin at the dosage of 500 mg once daily for 5 days.

The bilateral commissural incisions were cleaned with dilute hydrogen peroxide and dressed with antibiotic ointment for 2 weeks, while the lips were moisturized with petroleum jelly for 2 weeks.

We removed any sutures present at 2 weeks and confirmed centrality of the implants. When sutures have dissolved and incision sites were fully healed, we recommended to all patients to perform a regimen of stretching and tightening exercises for 3 months, 3 times a day, 15 repetitions each: open big, smile wide and pucker.

Follow up visits were performed every week for the first month and at 6 weeks, 6 and 12 months.

Complications after implantation of the prosthesis were evaluated every week for the first month and methods to avoid such complications were described.

#### Patients' evaluation

The evaluation of patients was carried 1 year after the procedure. Information about patient satisfaction, the natural effect for the patient and for the partner, the suggestion of the technique to other persons and the comparison to other techniques were collected.

In detail, the level of satisfaction of the patient was evaluated using a 6-point scale from *Extremely Satisfied* to *Very Dissatisfied* while the rating of the natural result for the patient and for the partner was assessed using a 4-point scale from *Extremely Natural* to *Not Natural*. A 5-point scale, from 1 to 5, with 5 being the highest mark, has been used in order to assess the recommendation of the procedure and to compare this technique to eventual previous procedures to which the patient underwent for lip augmentation.

Statistical evaluation was carried out with the SPSS statistical package (IBM, Armonk, NY, U.S.A.). To estimate correlation between variants, Pearson  $\chi^2$  or Fisher test were performed.

## RESULTS

Study population included 100 Caucasian women with mean age of  $33\pm 9.5$ . In our study all patients underwent a bivertical lip augmentation, whereas none of them was elected to have exclusive upper or lower augmenting.

Regarding diameter of final implant placement, 4 mm (93%) was the most used, while 3 mm (7%) was reserved for extremely thin and atrophic lips. The 5-mm-wide model was not used.

### Patients' evaluation

53% were *Very Satisfied* and 40% *Extremely Satisfied* and described their result as *Extremely Natural* (46.7%) and *Very Natural* (46.6%). Among these 93% patients, 86% of them rated the look and the feel of their lips as *Extremely Satisfied* as well as *Extremely Natural* (Figure 2a,b). 7% of patients were lost during the follow up.

Furthermore, score for recommendation of the technique to others was 4.7 while comparison with filler implantation ranked 4.8.

### Adverse events

Complications related to the procedure were grouped into acute and late side effects. The former included swelling, bruising and depth malposition while the latter were mainly represented by lateral malpositions.

Swelling and bruising were observed after the procedure in almost all patients. In particular, we report herein one case of severe swelling in a patient that had been treated with hyaluronic acid filler six months prior to the surgery (Figure 3). Figure 4 shows the course of an ecchymosis associated with erosions, resolved without sequelae in 3 weeks.

In 9 patients (9%) a progressive lateral malposition of the prosthesis was observed; of these, 90% (8 patients) concerning only the upper lip (Figure 5) and 10% (1 patient) both lips. In 5 patients (5%) a

depth malposition was detected. These patients were treated with a successful second implant with the exception of one case in which the patient asked the removal of both the prosthesis. After 12 migration revisions in the first 40 patients (30%) we decided to modify the technique and only 2 of the remaining 60 patients (3%) underwent revision for implant migration.

Infections, capsular contraction or rupture were not observed and no patient experienced a permanent impairment sensation. Additionally, implant buckling was not encountered in our patients.

### Tips and Tricks

Swelling and bruising were very common self-limiting adverse events. In order to decrease the swelling faster, cold compresses or ice packs for the first 3 days were suggested. On the other hand, patients were asked to abstain from smoking, alcohol, aspirin, ibuprofen, and any other herbal supplements or medications known to promote bleeding for two weeks or at least one week before treatment in order to reduce the risk of bruising. Furthermore, bruising usually takes about a week to resolve and a concealer to hide it during this period of time can be used.

Malposition is a complication affecting the result of this lip implant. In our experience, after 12 cases of lateral malposition we decided to modify the technique. Instead of the 4-5 mm transverse commissural incisions, without crossing the vermilion border, a blue dot line was drawn at the junction of the dry/wet mucosa and the dissection was limited to 2 mm from the blue line. This variation narrowed the tunnel, reducing the space for a possible migration. We underline that the incision must be made in the commissure in order to prevent medial displacement.

Moreover, closure is traditionally performed using 4-0 chromic catgut in a simple interrupted or figure-of-eight technique with 6-8 knots, which must be situated buccally if a figure-of-eight technique is used. Then, we decided to perform the U-suture with a braided absorbable stitch. Regardless of suture technique, however, it is essential to incorporate deep sub-mucosa and even muscle within each stitch.

In order to avoid depth malposition, we decided to perform a deeper dissection between the deep sub-mucosa and the muscle. In particular, straight operating scissors 3-1/2" were used in order to create a tunnel, using a very narrow opening.

An important key point for obtaining an excellent aesthetic result is the correct choosing of the prosthesis. The 4-mm-wide model represents the standard to utilize and is the most frequently inserted in the clinical practice, while 3-mm and 5-mm size are respectively used for patients with small lips and big lips or in whom request an additional volume. Regarding the correct choosing of the length of the prosthesis, it is very important to select the model without wide-opened mouth. In fact, an optimal length is several millimeters shorter than the distance from commissure to commissure and we suggest to measure this distance with a paper ruler along the wet-dry border of slightly parted lips. The upper lip, due to its curvature, sometimes requires a slightly longer implant, as compared to the lower lip.

To prevent the risk of dehiscence and malposition of the prosthesis, it is important that patients refrain from massaging their lips before the sutures have dissolved and incision sites are fully healed. Afterward, it is recommended to perform a regimen of stretching and tightening exercises (open big, smile wide and pucker) prescribed for 3 months because these facilitate the healing process, allowing the lips to acclimate to all the extension, retraction, and compression forces produced and incurred during normal motion. Moreover, these exercises maintain capsule length and decrease tightness.

## **DISCUSSION**

Currently the agent of choice for lip remodeling is represented by hyaluronic acid injection. Injection site reaction (edema, pain, erythema, itching and ecchymosis), hypersensitivity reactions, infections, asymmetry, lumpiness, foreign body granuloma, nodules and cyst formation, vascular occlusion (it can be a localized occlusion, resulting in skin necrosis, or a distant occlusion, causing blindness or cerebral ischemic events) are possible adverse effects of hyaluronic acid filler.<sup>1,2</sup>

However, most of the complications associated with hyaluronic acid injection use are mild, transient and reversible.<sup>1</sup> Moreover, the rare vascular and infectious complications associated with hyaluronic acid filler injection can be minimized with a thorough understanding of facial vascular anatomy, proper injection techniques and meticulous skin preparation.

Nevertheless, hyaluronic acid fillers have a variable duration and require serial treatments leading to greater expense and collagen deposition, while other techniques can give a permanent result in order to guarantee cost-effective methods. Furthermore, some patients would not accept injectable fillers for the so-called “needle phobia”.<sup>1,4</sup> This context allowed the development of alternative techniques for lip augmentation, with autografts playing an important role.<sup>3</sup> Nevertheless, the implant of prosthesis can represent an optimal strategy for some patients since autologous fat is an expensive treatment, but the results are still temporary and also impaired by possible imperfections.<sup>1</sup>

The literature of the last 30 years reports cases of lip augmentation with several implants suitable for lips. In particular, interesting experiences were described with one of the latest available expanded polytetrafluoroethylene implant having a dual porosity that can reduce the incidence of complications like shrinkage and migration, which were very common with lower porosity devices, but allowing vascular ingrowth that can lead to capsular contractions;<sup>5-9</sup> infections were reported in some cases.<sup>5,6</sup> Moreover, expanded polytetrafluoroethylene implants with their promotion of tissue ingrowth may restrict mobility and frustrate implant removal.<sup>4</sup>

More recently, soft silicon implants, such as PermaLip™, have been introduced.<sup>4</sup> Structural features and the permanent but easily reversible result represent major advantages of this prosthesis.

Furthermore, there is a reduced risk of capsular contractions in respect of expanded polytetrafluoroethylene implant and this is due to its smooth and nonporous surface, which resists tissue ingrowth.<sup>4</sup>

A previous study reported 12% of complications in 832 lip augmentations with the same implant on 420 consecutive patients during 5 years of experience, with malposition representing the most frequent (7%), followed by capsular contracture (1%), infection (<1%), hematoma (<1%), extrusion (<1%), need for size adjustment (<1%) and dissatisfaction (<1%).<sup>4</sup> Furthermore, Narsete et al. reported 18% of complications for 100 implants with two years of follow-up: migration with revision (10%), revision for size adjustment (4%), dissatisfaction requiring removal (4%)<sup>10</sup>.

In our study, based on three years of experience on 200 implants with PermaLip™ in 100 patients, we reported an intermediate rate of complications (14%), as compared to previous studies, represented by lateral malposition (9%) and depth malposition (5%), while implant buckling, infections, capsular contraction or rupture were not observed. Although these complications frequently occurred early in our series, their prevalence became very low after modifications in both intraoperative technique and postoperative instructions.

Our experience shows that variations in intraoperative technique lead to an improvement of results, reducing the rate of complications. In detail, a dissection limited to 2 mm, straight operating scissors 3-1/2" in order to create a tunnel, using a very narrow opening and closure with a U-suture with an absorbable stitch incorporating the deep sub-mucosa and even muscle within each stitch are introduced. The correct choice of the prosthesis remains an important factor to achieve the best results.

In addition, we detected important adverse events occurring early in the post-procedure. In particular, we observed a case of a severe edema in a patient that underwent several filler injections before lip prosthesis implantation and a case of a severe ecchymosis, without sequelae. None of the patients reported any sensory problem and all of these maintained normal lip function throughout the study.

Similarly to what has been previously reported,<sup>4</sup> patients' evaluation revealed a high degree of satisfaction with a natural result with patients recommending the procedures to others and considering the implant as giving long-lasting results as compared to filler injections. A significant

correlation between aesthetic satisfaction, natural results, recommendation of the technique and positive comparison with fillers has been found ( $p < 0,01$ ).

Interestingly, the 4-mm-wide model of PermaLip™ allows adequate tissue expansion for eventual 5-mm size placement. In patients with razor-thin lips the implantation can be performed only 3-6 months after a mucosal advancement or lip lift, which furnish extra tissue for inserting PermaLip™. A limit of lip implant is represented by the impossibility to modify lip asymmetry, which may be resolved with filler injections.<sup>4</sup>

The safety of lip implants and the satisfying result has been suggested.<sup>4,10-11</sup> Further studies involving more patients, with longer follow up, will be useful in order to evaluate long-term complications.

## CONCLUSIONS

The lip augmentation can be performed quickly, without significant morbidity, and the implants are easily inserted and can be revised in a few minutes, if needed.

PermaLip™ is permanent, reversible, pliable, follows natural contours, reduces long-term costs (as compared to non-permanent techniques) and improves pout and rhytides.

For optimal results and minimal complications we describe herein tips and tricks to better perform this technique and we suggest the importance of discerning in patient and implant selection.

We consider ideal candidates for lip augmentation the patients with normal philtral height and short labial height.

## References

1. San Miguel Moragas J, Reddy RR, Hernández Alfaro F, Mommaerts MY. Systematic review of "filling" procedures for lip augmentation regarding types of material, outcomes and complications. *J Craniomaxillofac Surg.* 2015;43:883-906.

2. Moragas JS, Vercruyssen HJ, Mommaerts MY. "Non-filling" procedures for lip augmentation: a systematic review of contemporary techniques and their outcomes. *J Craniomaxillofac Surg.* 2014;42:943-952.
3. Byrne PJ, Hilger PA. Lip augmentation. *Facial Plast Surg.* 2004;20:31-38.
4. Raphael P, Harris R, Harris SW. Five-year Experience with Perma Facial Implant. *Plast Reconstr Surg Glob Open.* 2014;2:e153.
5. Niamtu J 3rd. Advanta facial implants. *Oral Maxillofac Surg Clin North Am.* 2005;17:29-39.
6. Niamtu J 3rd. Advanta ePTFE facial implants in cosmetic facial surgery. *J Oral Maxillofac Surg.* 2006;64:543-549.
7. Fezza JP. Advanta implants. *Facial Plast Surg.* 2004;20:185-189.
8. Hanke CW. A new ePTFE soft tissue implant for natural-looking augmentation of lips and wrinkles. *Dermatol Surg.* 2002;28:901-908.
9. Truswell WH. Dual-porosity expanded polytetrafluoroethylene soft tissue implant: a new implant for facial soft tissue augmentation. *Arch Facial Plast Surg.* 2002;4:92-97.
10. Narsete T, Ersek R, Narsete MP. Further experience with permafacial implants for lip augmentation: a review of 100 implants. *Aesthet Surg J.* 2011;31:488-492.
11. Narsete T, Ersek R. Lip augmentation in conjunction with facelift: preliminary experience with a new permanent implant. *Aesthet Surg J.* 2009;29:356-359.

### Figure legends

**Figure 1.** Intra-operative images showing (a) dissection just below the sub-mucosa after commissure incision with scissors and (b) a tendon passer placed into the upper lip, by which the implant is then pulled across the lip.

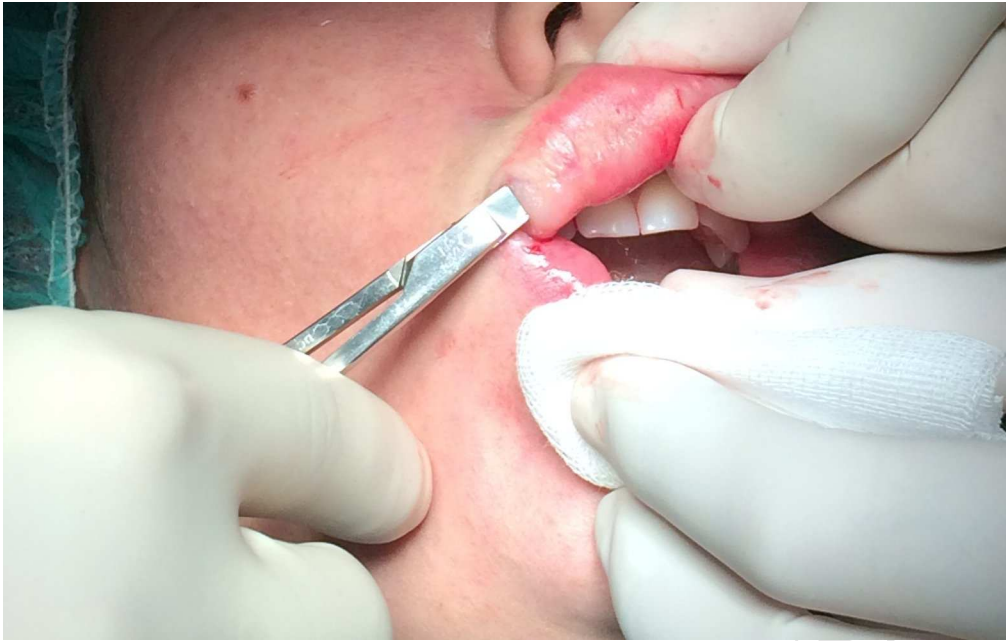**Figure 2.** A young woman before (a) and one year after 4 mm upper and lower lip implants (b).

**Figure 3.** A patient with a severe edema in a woman who was treated with hyaluronic acid 6 months before.

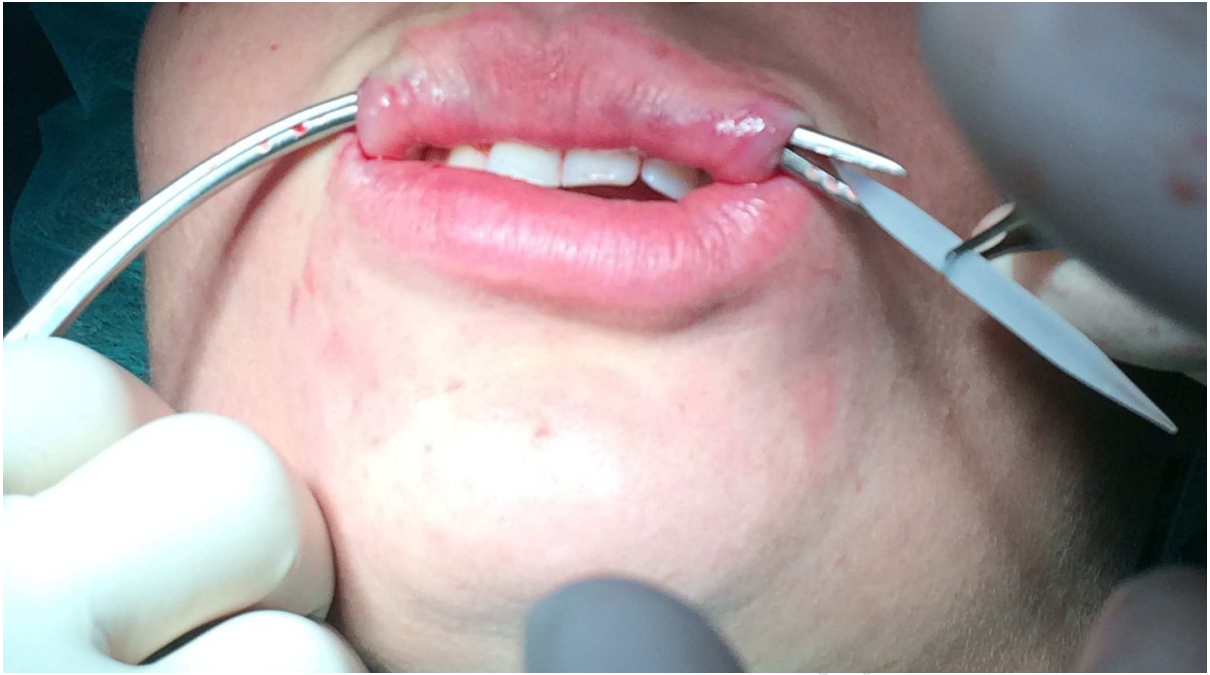**Figure 4.** A patient before (a), immediately after (b), one week after (c) and three weeks after (d) lip implants.

**Figure 5.** A patient showing lateral extrusion of the upper prosthesis.

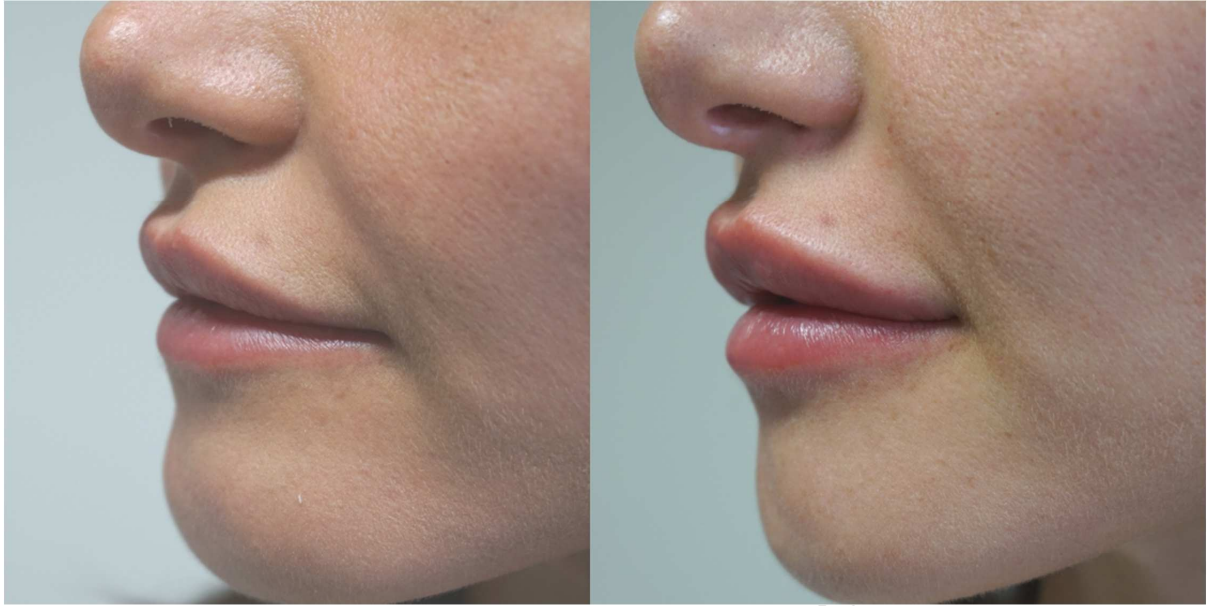ACCEPTED MANUSCRIPT



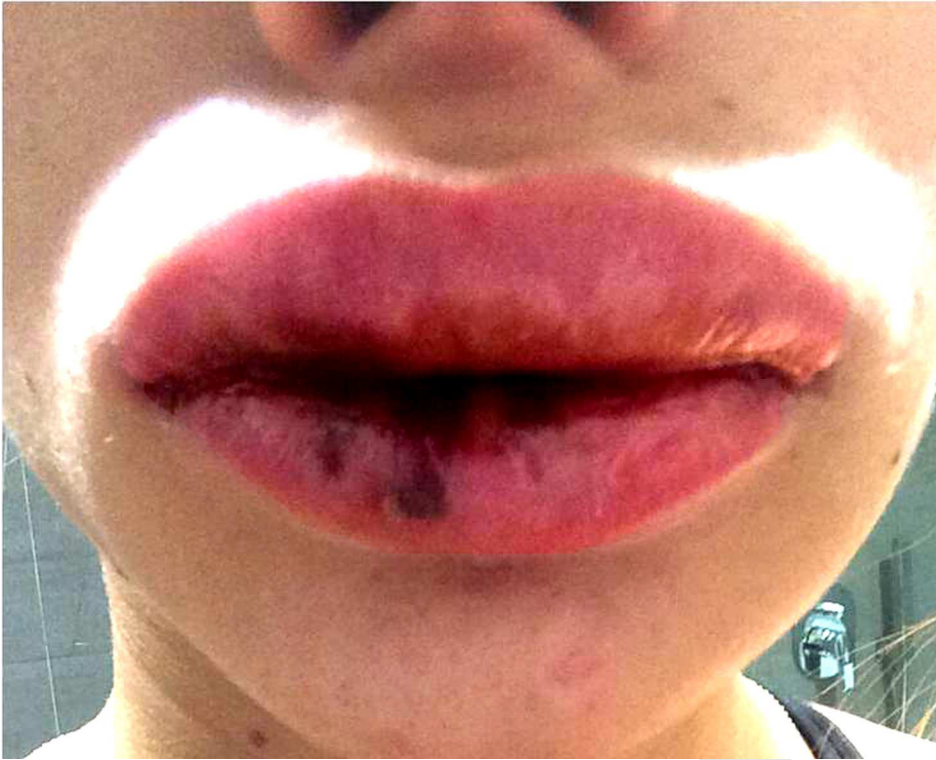
ACCEPTED MANUSCRIPT



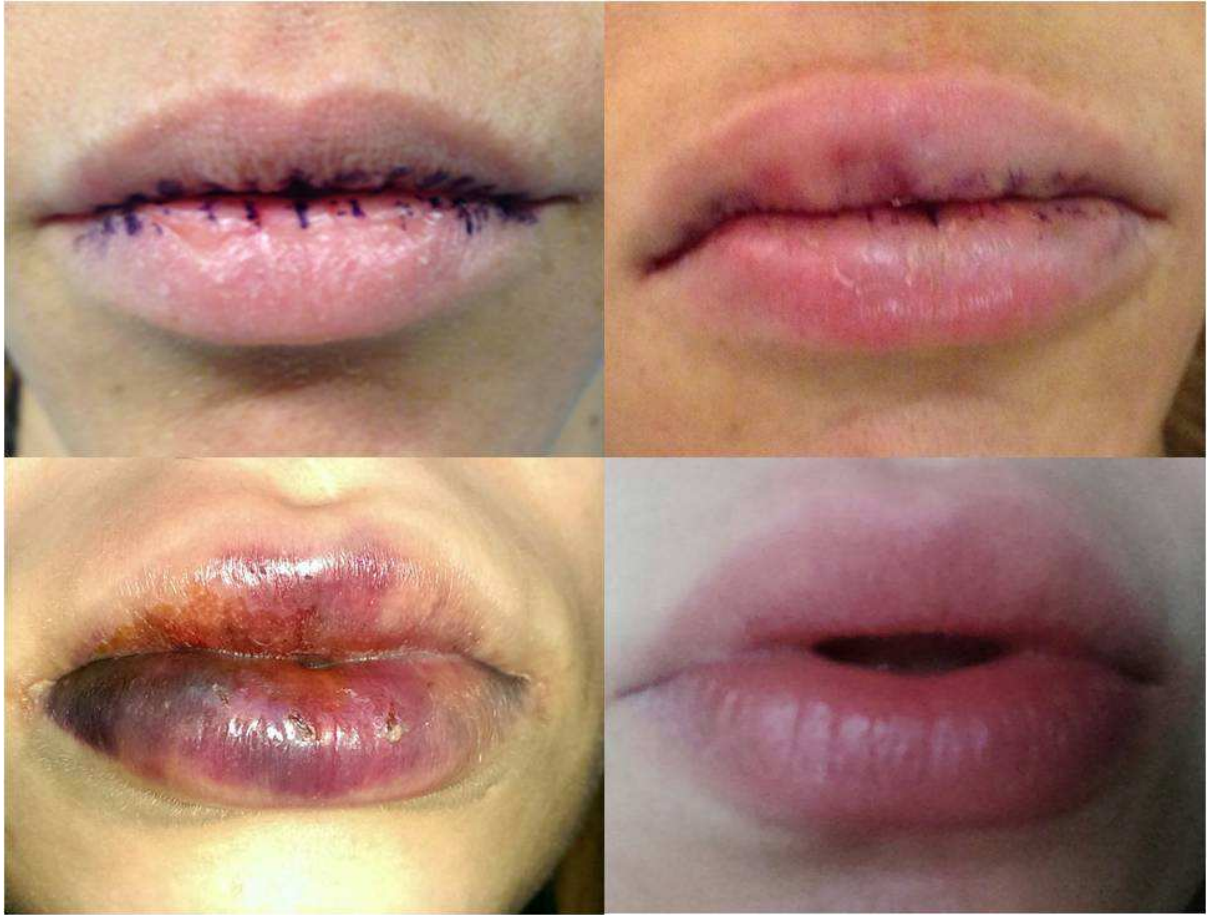ACCEPTED MANUSCRIPT



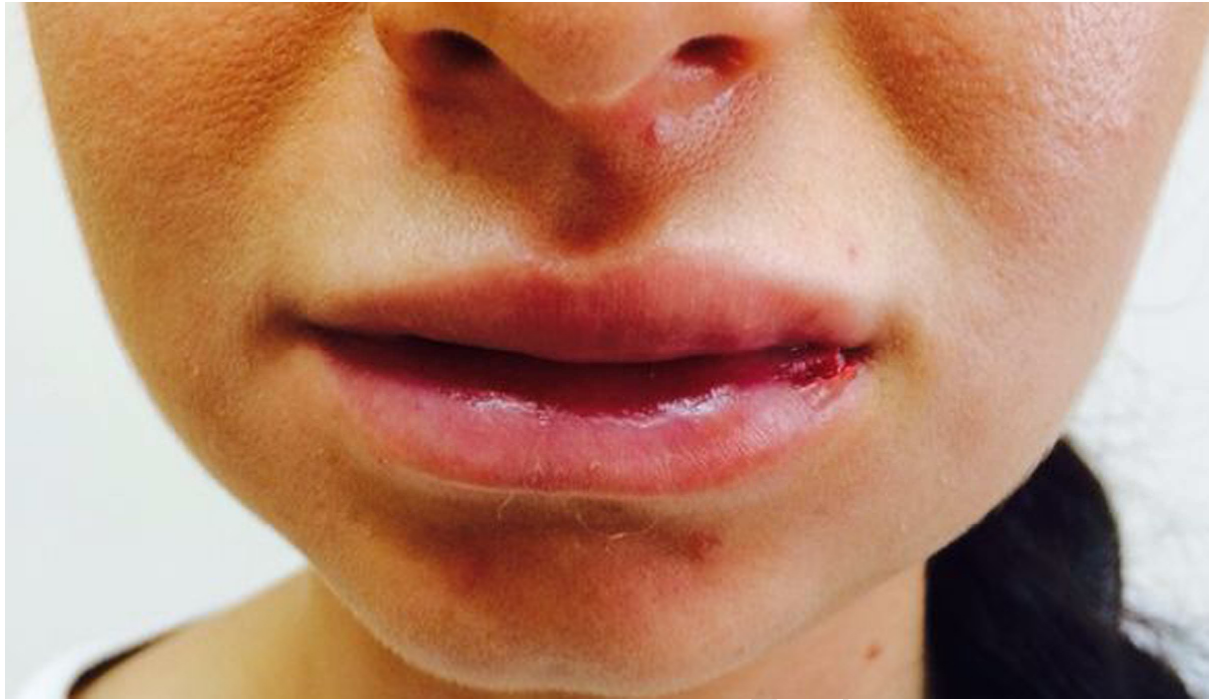ACCEPTED MANUSCRIPT



ACCEPTED MANUSCRIPT



ACCEPTED MANUSCRIPT



ACCEPTED MANUSCRIPT