

This is the peer reviewed version of the following article:

Urinary Continence Recovery after Radical Prostatectomy-Anatomic/Reconstructive and Nerve Sparing Techniques to Improve Outcomes / Pavlovich, Christian P; Rocco, Bernardo Maria Cesare; Druskin, Sasha C; Davis, John W.. - In: BJU INTERNATIONAL. - ISSN 1464-4096. - 120:2(2017), pp. 185-196. [10.1111/bju.13852]

Terms of use:

The terms and conditions for the reuse of this version of the manuscript are specified in the publishing policy. For all terms of use and more information see the publisher's website.

16/05/2026 04:31

(Article begins on next page)

DR. JOHN W DAVIS (Orcid ID : 0000-0003-3491-7194)

Received Date : 14-Dec-2016

Revised Date : 05-Feb-2017

Accepted Date : 27-Feb-2017

Article type : Review

Article type: Review

Article Category: Review

Title: Urinary Continence Recovery after Radical Prostatectomy—Anatomic/Reconstructive and Nerve Sparing Techniques to Improve Outcomes

Authors: Christian P. Pavlovich¹, Bernardo Rocco², Sasha C. Druskin¹ and John W. Davis³

1-Brady Urological Institute, Johns Hopkins University School of Medicine, Baltimore, MD

2-Ospedale Policlinico e Nuovo Ospedale Civile, S. Agostino Estense, Modena, University of Modena and Reggio Emilia

3--MD Anderson Cancer Center, Houston Texas

Corresponding author email id: JohnDavis@mdanderson.org

This article has been accepted for publication and undergone full peer review but has not been through the copyediting, typesetting, pagination and proofreading process, which may lead to differences between this version and the Version of Record. Please cite this article as doi: 10.1111/bju.13852

This article is protected by copyright. All rights reserved.

Abstract:

In an editorial board moderated debate format, two experts in prostate cancer surgery are challenged with presenting the key strategies in radical prostatectomy that improve urinary functional outcomes. Dr Bernardo Rocco was tasked with arguing the facts that support the anatomic preservation and reconstruction steps that improve continence. Drs. Christian Pavlovich and Sasha Druskin were tasked with arguing the facts supporting neurovascular bundle and high anterior release surgical planes that improve continence. Associate Editor John Davis moderates the debate, and outlines the current status of validated patient questionnaires that can be used to evaluate urinary continence, and recent work that allows measuring what constitutes a "clinically significant" difference that either or both of these surgical techniques could influence. A review of raw data from a publication from Dr. Pavlovich's team demonstrates how clinically relevant differences in patient reported outcomes can be correlated to technique. A visual atlas is presented from both presenting teams, and Dr. Davis demonstrates further reproducibility of technique.

Introduction.

Radical prostatectomy (RP) is a standard option for localized prostate cancer (PCa), and may provide the strongest odds of avoiding cancer-specific mortality, metastatic progression, and/or androgen deprivation compared to watchful waiting or radiation therapy [1-5]. From a logistical standpoint, post-operative monitoring with PSA is highly sensitive and convenient, and the pathologic staging provides robust disease-recurrence prognosis, and tissue available for genomic classifiers [6]. Although minimally invasive options are common, the surgery is nevertheless invasive compared to radiation alternatives, and the surgical side effects men fear include urinary incontinence and sexual dysfunction [7]. One could hypothesize that a durable solution for functional side effects would have a significant impact on treatment selections and satisfaction. In this review, we will focus on the urinary

Accepted Article

continence side effect with two key points of debate in the literature that propose to improve outcomes: 1) anatomic/structural preservation and reconstruction, and 2) nerve preservation planes. Our format will begin with a methodology review by Associate Editor John W. Davis, and then we will proceed with reviews from Team Rocco for the structural arguments, and Team Pavlovich for the nerve sparing arguments.

Associate Editor John W. Davis's Review of Baseline Urinary Incontinence Data after Radical Prostatectomy—How We Measure and How Good Are We?

Upon initial review of the topic of prostate cancer treatments, patient perception of the risk of urinary continence after RP is likely severe. Many high profile online publications such as American Cancer Society [8] and the United States Preventative Services Task Force [9] contain verbiage that could be interpreted as implying that all post-prostatectomy patients suffer from incontinence, and there are often minimal qualifiers as to how long or how severe. This problem is compounded by the observation that physician (surgeon) estimation of urinary continence is too optimistic compared to patient reported data—especially the risk of “minor” incontinence [10].

In the late 1990's and onward, outcomes researchers from the University of California Los Angeles and the University of Michigan constructed patient reported quality of life (QOL) surveys, and validated them in numerous populations with prostate cancer treatments, and utilized formal test metrics [11-12]. These studies established new standards for QOL studies:

- Urinary, Sexual, Bowel, and Hormonal functions are the key disease-specific domains for PCa-QOL.

- Accepted Article
- Urinary, Sexual, Bowel, and Hormonal bother are separate domains, which address how much a patient's current function causes them problems. These domains are distinct from function, and reflect long-standing observations that an individual patient may adapt to functional loss and report different levels of bother depending upon their age, expectations, and other factors.
 - The UCLA survey, and the Michigan updated survey "EPIC" (expanded prostate cancer index composite) use a series of Likert-like questions with 3-5 possible answers scaled longitudinally from 0 points for the worse result and 100 points for the best result. Each domain (e.g. urinary function) is a cluster of questions where all of the 0-100 scores are averaged together—higher numbers always the better outcome.
 - Although cross-sectional data (1 measurement per patient—often varying ranges of follow-up averaged together) with "normative" controls have been published, the ideal methodology is for each patient to be surveyed at baseline and then 3-6 month intervals post-treatment for several years [7].
 - Post-validation, additional study is required to determine what difference between two treated groups would be considered "clinically significant" as distinct from statistically significant. The former is a fixed delta, whereas the latter is a function of sample size.
 - Despite the depth of information built into QOL surveys, patients may be ill-equipped to understand them, and may still request the simple binary result measurement: "What is your continence rate?" Researchers may attempt to accommodate this desire for simplification by taking a single question from an EPIC survey, "Which of the following best describes your urinary control during the last 4 weeks," and reporting the percentage of respondents that answer #4, for "Total control." Another research may allow answer 3 or 4 (total control or occasional dribbling) and thus the common observation that "continence rates depend upon the definition."

Accepted Article

For baseline urinary function, several studies using the EPIC have found mean scores of approximately 90-93 [7, 13-15]. Before considering specific results, Skolarus et al [16] provided a recent guide to understanding the “clinical” significance question. Using data from the PROSTQA consortium, they utilized a distribution method, and an “anchor-based method.” These two methods consider standard deviation of baseline and post-treated scores as well as how domains affect each other. The combined methods generated a “Minimally Important Difference” of 6-9 points for urinary incontinence (each domain has its own range). Therefore if the average baseline for urinary incontinence is 90, then a recovered score of 81 or greater would start to meet the definition of “no clinically significant difference.”

So how far away are we from declaring urinary incontinence as a moot point? The gold standard study on the topic was published by Sanda et al on behalf of the PROSTQA study [7]. This funded study grouped 11 academic centres with baseline and follow-up EPIC QOL surveys, and included surgery, radiation, and brachytherapy. The surgery cohort had the typical baseline of 90, and in the 2-3 month post-op range it dipped to 50, and then recovered quickly to 70 by 6 months, and just under 80 at 12 months. Nerve sparing cases were slightly better than non-nerve sparing, and the curve clearly plateaued from 12-24 months postoperatively. Therefore, we can conclude that improvements to urinary control could be measured at the healing time interval, and/or the final “healed” result, which currently appears to be 12 months. Other published studies using EPIC also showed “healed” results of 79 from Wei et al [13], 76-77 from Willis [17], and 74 from Alemozaffar et al [18].

In summary, the unmet needs for improving urinary control after RP include 1) improve the final healed result into the mid-80’s on the EPIC scale, and 2) decrease the length of

Accepted Article

recovery to < 3-6 months. These expectations set the stage for our two teams to argue two different bodies of literature that purport to move us in this direction.

Team Rocco: Urinary Control is Improved from Apical Dissection and Anatomic Reconstruction.

APICAL DISSECTION

Dissection of the prostatic apex represents a critical moment in radical prostatectomy, because of the position deep in a narrow portion of the pelvis, and its close connection to the dorsal vein complex (DVC--or plexus Santorini), rectum, neurovascular bundles, and rhabdosphincter [19]. The external urethral sphincter is an omega-shaped muscle consisting of an external striated part and an internal smooth muscle layer [20-22]. Its fibres surround the urethra, which length lies in the range of 1.5 to 2.4 cm. A considerable part of it is located intraprostatically between the apex of the prostate and the colliculus seminalis [23]. In addition, the urethral sphincter is covered by the DVC and ridges of rudimentary striated muscle fibres [24] and the posterolateral aspect by the prostatic apex and neurovascular tissue [22]. This may compromise the full-length urethral sphincter preparation during RP.

According to the technique we imply for robotic-assisted RP (RARP), apical dissection is performed after complete mobilisation of the prostate [25]. We usually ligate the DVC after the endopelvic fascia dissection, and we suspend it to the pubic bone with a second suture according to the technique described by Patel et al.: the aim of this technique is the stabilization of the urethra avoiding urethral retraction, facilitating the urethral dissection [26]. A ligature of the DVC is beneficial especially for surgeons in their learning curve [27], as it prevents bleeding which may interfere with the apical dissection and division of the urethra

under direct vision [25]. Another option is the compression of larger vessels with a sponge stick or the use of a bulldog clamp [28].

Some surgeons prefer to perform an athermal division of the DVC followed by a selective suture ligation. When performing this kind of technique in laparoscopy, it may be useful to increase the intra-abdominal pressure to 20 mmHg to prevent blood spillage from the DVC [29]. In a prospective nonrandomized comparative study, Lei et al. reported significantly better 6-months urinary continence rates in patients who underwent DVC division followed by selective suture ligation prior to anastomosis, in comparison with those receiving suture ligation prior to bladder neck dissection [30].

After the division of the DVC, the prostate is separated from the urethral sphincter by a blunt dissection and cut with the scissors without cautery for maximal preservation of the neurovascular bundle. The tissue covering the prostatic part of the sphincter is gently pushed cranially until the underlying longitudinal smooth muscle becomes visible. The longitudinal smooth muscle fibres can be followed intraprostatically by a blunt dissection and retraction of the apical tissue. It was shown by pelvic magnetic resonance imaging (MRI) studies that an increased risk of shortening the urethra is present when the prostatic parenchyma covered the muscular urethra [31].

The anterior part of the urethra is then transected until the transurethral catheter becomes visible. Then the catheter can be retracted and the dorsal urethra is divided. For a better visualisation of the apical region, we use a 30° binocular lens directed downwards. Tewari et al. described an alternative technique, using a 30° upward-facing lens in combination with retraction of the prostate [32]. Using this technique, they reported a reduction in the rate of positive surgical margins (PSM) from 4.4% to 1.4%. In case the apical region of the prostate is suspicious for a PSM or residual tumour cells are left behind in the urethra, an

Accepted Article

intraoperative frozen section should be performed. Biopsies at the apex of the prostate as well as from the urethral resection site are helpful to predict a positive surgical margin, but in fact there are not much further therapeutic surgical options in this area, since more aggressive treatment may result into a higher rate of urinary incontinence [33]. For clinically high-risk tumours and when full functional-length urethral sphincter preservation is intended, frozen sections in this area could reduce PSM rate [34].

POSTERIOR MUSCULOFASCIAL PLATE RECONSTRUCTION TECHNIQUE

In 2006, Rocco F et al. proposed a technique for reconstruction of the posterior aspect of the rhabdosphincter (RS), which has been suggested to shorten time to continence in patients undergoing retropubic RP [35]. In 2007, Rocco B et al. described the application of the posterior reconstruction technique to transperitoneal laparoscopic radical prostatectomy (LRP) [36], while, in 2008, Coughlin et al. applied the posterior reconstruction of the rhabdosphincter to RARP with some minor technical modifications [37]. The technique has been further modified in 2011 [38].

The reconstruction is performed using two 3-0 poliglecaprone (Monocryl® Ethicon, Somerville, NJ, USA) sutures (on RB-1 needles) tied together, with each individual length being 12 cm. Ten knots are placed when tying the sutures to provide a bolster. The free edge of the remaining Denonvillier's fascia is identified after the prostatectomy and approximated to the posterior aspect of the rhabdosphincter and the posterior median raphe using one arm of the continuous suture. As a rule, four passes are taken from the right to the left (**Figure 1**). The second layer of the reconstruction is then performed with the other arm of the suture approximating the posterior lip of the bladder neck (full thickness) and the vesicoprostatic muscle, as described by Walz et al. [22], to the posterior urethral edge and to

the already reconstructed median raphe (**Figure 2**). This suture is then tied to the end of the first suture arm.

One of the key steps for an appropriate reconstruction is the preservation of the Denonvillier's fascia when dissecting the posterior plane between the prostate and the rectal wall. If this dissection is performed at the perirectal fat tissue, the Denonvillier's fascia is not adequately spared, precluding posterior reconstruction.

A systematic review showed that the reconstruction of the posterior musculofascial plate improves early return of continence within the first 30-45 days after RP; in the same study, trend towards lower anastomotic leakage rates has been found in patients who received the posterior reconstruction [39]. Furthermore, the Pasadena Consensus Panel for Best Practices in RARP found unanimous agreement that posterior reconstruction may facilitate performing the urethrovesical anastomosis and reduce bleeding [40]. The results of the European Association of Urology Robotic Urology Section (ERUS) survey of RARP showed that the posterior reconstruction of the musculofascial plate is usually performed by 51.7% of surgeons, and sometimes by 19.8% [41].

Team Pavlovich: The Effects of Nerve-Sparing Approaches to Radical Prostatectomy on the Recovery of Early Urinary Continence.

The nerve-sparing (NS) approach to radical prostatectomy was developed in an effort to allow for the recovery of erectile function (EF) after surgery. While oncologic control is its primary consideration, the preservation of peri-prostatic tissues, especially posterolaterally (where the neurovascular bundles of Walsh (NVBs) are located), has allowed for improved postoperative quality of life (QOL) [42]. It is clear that the major significance of NS relates to

the recovery of EF; when both nerves are sacrificed, spontaneous potency virtually never returns, while greater degrees of NVB-sparing lead to improved recovery of EF [43-44]. But are there reasons to consider that a NS approach to RP might also aid in the recovery of urinary continence (UC)? It appears so. Firstly, meticulous anatomic preservation of the NVB generally also preserves the supportive tissues that invest the prostate gland. These tissues in turn ramify toward the prostatic apex and distal urethra, the integrity of which is important for UC. Secondly, an atraumatic approach to NS, including minimizing electrocautery and traction injury, should theoretically minimize such damage to structures involved in physiologic UC. Thirdly, the external urethral sphincter is innervated by both autonomic nerve fibers from the pelvic plexus and somatic nerve fibers from the pudendal nerves [45-46], and some nerve fibers along the NVB also innervate the membranous urethra [47]. These nerves, plus autonomic afferents and structures involved in the membranous urethral microcirculation may be compromised by non-NS/wide excision RP [48-49]. The nerve fibers likely involved in continence recovery after RP, which tend to run more anteromedially particularly around the prostatic apex, are more likely spared with “high anterior release” [50] or “veil” [51] approaches to NS. Despite these arguments for the effects of NS on UC recovery, there are many patients who are either preoperatively impotent and/or who have non-NS surgery who nevertheless regain UC post-RP. Therefore, the effects of NS on UC, while potentially real, may be subtle and may at least in part involve supportive structures rather than fully functional nerves.

Here, we review the current data on the association of NS with recovery of UC in men undergoing RP. While there is little level-1 evidence in this area, there are many non-randomized retrospective and prospective cohort studies as well as a large and recent meta-analysis and review on this topic [52].

EFFECTS OF NVB-SPARING ON LONG-TERM URINARY CONTINENCE OUTCOMES

The vast majority of patients will regain UC within a year or two after RP, after which outcomes plateau [42-43, 53-55]. Risk factors for long-term (>1-2 years post-RP) urinary incontinence (UI) include increasing patient age, the development of anastomotic stricture, and non-NS surgery, with increasing age appearing to be the most important risk factor [55-57]. Anastomotic strictures are all but disappearing in the robotic era, but the effect of NS on long-term UC outcomes remains controversial. Well-respected groups from a variety of countries have presented conflicting retrospective data – increasing categorical sparing of 0, 1, or 2 NVBs has been shown to improve long-term UC by some [54-57], while others have found no detectable effect [43,53]. A similarity between the series cited that did not demonstrate an effect of NS on long-term UC is that the vast majority of their patients (~90%) underwent bilateral NS, resulting in very small comparison (unilateral and non-NS) groups [43,53]. The excellent long-term UC rate in these studies and the high percentage of their patients who received NS contributes to the argument for the potential effects of NS on the recovery of UC. Of note, these authors did not present data on early recovery of UC, which may be more affected than long-term recovery by NS. Studying only long-term data indeed presents particular challenges: men may have gone on to have UC procedures missed by the study team (e.g. artificial urinary sphincter or sling, generally performed only after a year or more of UI), for example. Patients may also have undergone adjuvant procedures, such as radiation therapy for a positive surgical margin, that go under-reported, possibly confounding long-term UC results in men with more advanced disease. Time periods under a year postoperatively are less likely to contain these types of contamination and more likely to demonstrate any subtle effects of NS or partial NS on UC recovery. Furthermore, psychological distress during the first year after RP is tightly associated with UI, rather than with erectile dysfunction [58]. Elucidating the effects of NS on short-term recovery of UC may have implications in surgical planning, especially in impotent patients, in whom NS may be deferred by some surgeons if it is seen as not beneficial.

EFFECTS OF NVB-SPARING ON SHORT-TERM URINARY CONTINENCE OUTCOMES

It is difficult to differentiate between NVB-sparing, and the sparing of the supportive tissues associated with the NVBs. Most surgeons simply state that NS was either performed, or not. However, partial NS surgery has been performed for years, and was indeed discussed at least as far back as 1991 [59]. NS grading systems have been developed in order to estimate the extent of NVB preservation, and are currently in use by multiple groups [44, 60-62]. Gradations of NS are determined by intraoperative visual inspection, and correlate closely with the recovery of potency [44, 60, 62]. Are gradations of NS relevant to urinary convalescence as well? At least one group has addressed this in series of men with mixed preoperative potency status [63]; at least two groups have looked at this question in preoperatively *potent* men exclusively (with SHIM or IIEF scores in the top/normal range) [64-65], and at least two groups have looked at this question in preoperatively *impotent* (SHIM <15) men [66-67].

STUDIES OF CONTINENCE IN PREOPERATIVELY *POTENT* MEN

Kaye et al. [64] conducted a prospective trial in which 99 preoperatively potent men under age 65 having laparoscopic or robotic RP by 3 surgeons at a single institution had NS graded at the time of surgery using a NS score of 0-4 per side, with 4 being the best (examples of NS depicted in **Fig 3 A and B**). The patients were followed by EPIC questionnaire for their UC outcomes at 0, 1, 3, 6, 9 and 12 months and virtually all had some degree of bilateral NS. In a mixed model analysis accounting for age, BMI, prostate volume and time from surgery, patients that had at least one NVB scored as a “4” (excellent -“intact bundle with significant supportive tissue veil/high release, no nerve visualized on specimen”) had superior urinary QOL scores and less pad use compared to patients without at least one “4” NVB, at all postoperative

time points. Bilateral excellent NS (both “4”) did not confer much in terms of urinary improvements compared to unilateral excellent NS (with lesser degrees of NS on the contralateral side). It is important to note that essentially all of these patients would have been recorded simply as having had both nerves spared by most surgeons; a grading system such as the one used here was able to tease out any contribution of sparing the anterior- and lateral-most NVB-investing tissues/structures to improved UC recovery, although these dissections were nevertheless interfascial rather than intrafascial.

Stolzenburg et al. [65] published a larger prospective study of 400 potent, low-intermediate risk men undergoing robotic RP with bilateral NS performed by multiple surgeons. Half were randomized to bilateral intrafascial NS, the other half to bilateral interfascial NS. UC was assessed by International Continence Society questionnaire at 3, 6, and 12 months postoperatively. UC was defined as 0 pads per day (PPD) or 1 safety pad. At 3 and 6, but not 12 months postoperatively, intrafascial NS patients had significantly superior UC by reported pad usage than patients who had interfascial NS, although no multivariable analysis was done. These data, as well as the data of Kaye et al. [64] above, provide support to the notion that the structures closely adherent to the prostate laterally and anteriorly may aid in the short-term recovery of UC. These structures are spared when an entire NVB is spared, either intrafascially or with a high anterior release/excellent NS, but whether the UC improvements are related to actual neurons (e.g. somatic nerve fibers to the rhabdosphincter), membranous urethral vasculature, and/or the structural support that periprostatic tissues provide remains unclear.

STUDIES OF CONTINENCE IN PREOPERATIVELY *IMPOTENT* MEN

Khoder, et al. [66] published a study of 420 impotent men (IIEF<15) with localized prostate cancer who were treated with bilateral NS RP. 239 received intrafascial RPs for Gleason Score (GS) 6 or less and PSA 10 ng/mL or less; 181 received interfascial RPs for GS 7 or less and PSA >10 ng/mL. A control group of 77 men undergoing non-NS RP was used. There was no significant difference in UI between each group at 3, 12, and 36 months after surgery; however, there was a non-significant superiority of NS to non-NS for each of the time points for 0 PPD UC, and in men >70y, there was a higher proportion with full UC at 36 months in the NS group (p=0.052).

Takenaka et al. [67] reported on a subset of impotent (IIEF < 14) men receiving laparoscopic RP. In this subset, attempted NS was associated with improved UC rates on both uni- and multi-variate analyses at the 3- and 6- month postoperative time points.

META-ANALYSIS OF NERVE-SPARING VS NON-NERVE-SPARING ON EARLY CONTINENCE

A systematic review and meta-analysis of whether preservation of the NVB is associated with UC outcomes after RP was recently reported by Reeves et al. [52]. This assessment of the available literature was thorough and comprehensive, although, as with all meta-analyses, it consists of studies with a great heterogeneity of patients and outcome measures - in this case, UC assessment tools. The authors included 27 cohort studies in their review (some prospective, some retrospective, some unclear in design) conducted between 1983 and 2011 that included almost 14,000 patients who had either NS or non-NS RP. They did

not include studies only comparing one degree of NS with another (e.g. intrafascial to interfascial) if there was no non-NS 'control' group; thus, studies such as those by Kaye, Stolzenburg, Takenaka, and Khoder et al., cited previously [64-67], were not considered in this meta-analysis. They did analyze bilateral and unilateral NS subgroups when available, but did not take into consideration gradations of NS at any one NVB. Inconsistencies existed in the definitions of NS and UC, as well as in baseline patient characteristics (e.g. preoperative UC; prior TURP) between studies, as expected given the variety of studies reviewed.

UC was assessed by meta-analysis at multiple postoperative time points: 6 or fewer weeks, and 3-4, 6, 12, and 24 months. When comparing any NS to no NS, the rate of UC for those who had NS was higher at the 6 or fewer-week, 3-4-month, and 6-month time points. By 12 and 24 months, there were no differences between the groups. When comparing bilateral-NS to non-NS, the relationship was similar. At 6 or fewer weeks, patients receiving bilateral-NS had better UC than those receiving unilateral-NS; the two groups were found to be equivalent after that time point. Unilateral-NS was also found to have equivalent UC outcomes to non-NS for every time point studied. Taken together, these results suggest that bilateral-NS, when compared to non-NS, may produce higher rates of return of UC in the first 6 months after surgery, but may only outperform unilateral-NS for the first 6 weeks; standard unilateral-NS may not be superior to non-NS. However, these results must be interpreted cautiously, given the heterogeneity and missing data in the studies included in the analysis, and the small number of series looking at certain time-points (e.g. only 4 studies addressed the 6 month time-point). One of the most important pieces of missing data may be the degree to which the NVBs were spared, as NS scoring systems were generally not used in the studies analyzed with the exception of the study by Srivastava et al., one of the largest series analyzed [63].

Accepted Article

Srivastava et al. [63] reported on 1,500 preoperatively continent men undergoing NS robotic RP by a single surgeon, with graded NS quality predicted preoperatively based on risk-stratification that included PSA, clinical stage, GS, and multiparametric MRI, and then adjusted intra-operatively as needed. The actual degree of NS, and not the preoperatively planned degree of NS, was recorded, but if each of the two NVBs had different degrees of NS, the patient was recorded as having received the worse of the two degrees of NS. Thus, unilateral vs. bilateral NS comparisons were not made. They assessed UC, defined as 0 PPD over the prior 4 weeks, at 6 and 12 weeks postoperatively. They found that rates of UC return at 6-12 weeks postoperatively were significantly superior in patients with better qualitative degrees of NS.

Another of the larger series assessed in the meta-analysis was from Ko et al. [68], who prospectively collected data on about 1,300 men undergoing robotic RP with a peri-urethral suspension stitch and modified posterior reconstruction from 2008-2010. They collected UC data at 4 weeks, 6 weeks, and 3 months, and every 3-6 months thereafter using the EPIC questionnaire. UC was defined as 0 PPD and no reported leakage. Patients were grouped by extent of NS: no NS, complete bilateral NS, or partial NS (everyone not in the other two categories), as determined by the surgeon's subjective intraoperative assessment of NS. 21 variables were assessed for their association with regaining UC at or before 3 months. They found that about 86% of patients were continent by 3 months and that both partial and bilateral NS were associated with earlier median times to UC when compared to the non-NS group.

SYNTHESIS

The available literature provides support to the contention that early UC recovery is positively affected by NS, which at its best includes preserving as much of the anatomic cradle of the prostate as possible – its associated investing fasciae, its anterolateral tissues, and of course its posterolateral NVBs. While the effects of such tissue preservation may not have a great deal of impact on long-term UC outcomes, its positive effect on short-term UC outcomes argues for NS and the sparing of peri-prostatic tissue when it is oncologically acceptable to do so. The increasing use of preoperative multiparametric MRI and targeted biopsy strategies should make it easier to know when it is safe to perform aggressive NS and peri-prostatic tissue preservation with the intent of improving a patient’s chances of recovering both urinary control and of course erectile function.

In his Introduction, Dr. Davis asks the important question of whether nerve-sparing approaches to RP can bring validated urinary continence outcomes back to “baseline” using EPIC or a comparably validated questionnaire. In other words, *is a return to within 6-9 points of preoperative urinary scores, all normalized to 100, possible?* We found two manuscripts in the literature that shed partial light on this topic, one from Dr. Patel’s group [66] and one from our group [64]. Both datasets assessed nerve sparing and early recovery of urinary quality of life after RP and used the EPIC questionnaire. The raw data that went into Table 1 of the Kaye paper is presented here for the first time, and demonstrates that EPIC Urine Summary Score is influenced by nerve sparing quality, and is in fact statistically “back to baseline” (+/- 9 points) by 6 months in men who received *bilateral* excellent nerve sparing, and by 9 months in men who received *unilateral* excellent nerve sparing, but not in men who received lesser qualities of nerve sparing. These data suggest that, at least for young (<65) and preoperatively potent men, meticulous nerve sparing and preservation of the periprostatic supportive structures (e.g. “excellent” nervesparing) indeed impacts continence and is a contributor to early “back to baseline” urinary quality of life after RP.

Associate Editor Davis' Finish

In this review, we present multiple aspects of urinary continence after RP--quality of life, measuring progress, anatomic concept, and nerve-sparing concepts. Although presented almost like a debate, these are not either-or techniques to consider--both may be replicated/validated and put into your repertoire. **Figures 4-7** demonstrate a series of validation images in which another surgeon (JWD) is replicating the technique and data discussed by team Pavlovich. **Figure 7** shows the same concept--replicating/validating the Rocco/posterior reconstruction. With the advances in validated QOL surveys and interpretation, we can improve our ability to quantitate progress and design proper comparisons. Indeed, the next wave of "progress" is now being reported in the form of the "Retzius-Sparing" approach [69-70]. In this technique, the entire procedure is performed through the Pouch of Douglas. Although the posterior reconstruction and nerve sparing planes can be performed in the same manner, the additional hypothesis proposed is that preserving the complete anterior space of Retzius tissues provide additional bladder support and enhanced recovery of continence. A refreshing future will be the opportunity to have randomized data in this space. Mani Menon (Henry Ford, Detroit, MI, USA) has presented a single center randomized clinical trial of standard to Retzius sparing technique and publically reported results indicating advantages for Retzius sparing at 3 months [71]--Clinicaltrials.gov identifier NCT02352103. However, continence at 1 year returned to similar levels. This technique will add to our controversies on ideal technique, training, and learning curves.

In conclusion, urinary continence is a multifactorial process. In this debate-style review, we emphasize two areas emphasized in the literature, whereby a debater considers a question and then aligns literature around that question. In other styles of review, all aspects of a question like continence-sparing technique can be considered. Bessede et al [72] performed such a review, and with a wide catch search (urethral sphincter, urethral rhabdosphincter, urinary continence and nerve supply, neuroanatomy and nerve sparing), they found seventeen articles. Table 2 highlights the sub-topics on urinary continence that they

reviewed--a multifactorial contribution of anatomy preservation, reconstruction, and nerve preservation. Their conclusion agrees: "it is challenging to delineate the specific impact of periprostatic nerve sparing on continence, but the anatomical data suggest that RP surgeons should steer toward the preservation and protection of these nerves whenever possible."

FIGURES LEGENDS

- **Figure 1.** First layer of posterior reconstruction. The free edge of the remaining Denonvillier's fascia is approximated to the posterior aspect of the rhabdosphincter reconstruction
- **Figure 2.** Second layer of posterior reconstruction. The posterior lip of the bladder neck and vesicoprostatic muscle are sutured to the posterior urethral edge reconstruction.
- **Figure 3a-b.** These intraoperative images of robotic RP (surgeon-Pavlovich) demonstrate the left neurovascular bundle being spared to varying degrees during interfascial dissection. Image A. demonstrates nerve sparing grade 4 on a 0-4 scale with 4 being the best [61, 64] (the bundle is wide, high, and associated with a significant amount of associated tissue, without break from base to apex). Image B. depicts nerve sparing to a lesser extent, graded a 3 on the same 0-4 scale (the bundle is without obvious defect but is much thinner and has less surrounding vascular and supportive tissue remaining).
- **Figure 4—**Validation images. Robotic RP (Surgeon—Davis) for favorable risk disease. The high anterior release is completed, as retracted by the left hand grasper. The posterior lateral plane is now being developed. This demonstrates another surgeon's technique for table 1: bilateral excellent nerve sparing or grade 4).

- Accepted Article
- **Figure 5a-b.** Validation image—high-risk disease. Robotic RP (surgeon-Davis) demonstrating intended grade 3—nerve sparing but low release with no intent to spare anterior tissue. Image 5a—early nerve release step. Image 5b—nerve release turning to the apex.
 - **Figure 6a-b.** Validation images post resection—robotic RP (surgeon—Davis). In this same case for figure 4, the appearance is demonstrated of high anterior release. In image 6b—the same high risk case with low release. While standard, low release has the appearance often described as “train tracks” post resection, the high release looks more like a bowl.
 - **Figure 7a—Rocco validation.** Robotic RP from the favorable risk case (surgeon—Davis) shows the second step approximating the longitudinal layer under the bladder with the posterior rhabdosphincter. Image a shows a 3-0 Vicryl configure as a U-stitch, such that when tied (image b) the knot buries into the tissue to hold tension and allow easy approximation in < 2 minutes.

References

- 1) Bill-Axelson A, Holmberg L, Garmo H et al. N Engl J Med 2014; 370: 932-42.
- 2) Zelefsky MJ, Eastham JA, Cronin AM, et al. Metastasis after radical prostatectomy or external beam radiotherapy for patients with clinically localized prostate cancer: a comparison of clinical cohorts adjusted for case mix. J Clin Oncol 2010; 28: 1508-13.
- 3) Kibel AS, Ciezki JP, Klein EA, et al. Survival among men with clinically localized prostate cancer treated with radical prostatectomy or radiation therapy in the prostate specific antigen era. J Urol 2012; 187: 1259-65.
- 4) Sooriakumaran P, Nyberg T, Akre O, et al. Comparative effectiveness of radical prostatectomy and radiotherapy in prostate cancer: observational study of mortality outcomes. BMJ 2014; 348:g1502
- 5) Sun M, Sammon JD, Becker A, et al. Radical prostatectomy vs radiotherapy vs observation among older patients with clinically localized prostate cancer: a comparative effectiveness evaluation. BJU Int 2014; 113: 200-208.
- 6) Ross AE, D'Amico AV, Freedland SJ. Which, when, and why? Rational use of tissue-based molecular testing in localized prostate cancer. Prostate Cancer Prostatic Dis 2016; 19: 1-6.

- Accepted Article
- 7) Sanda MG, Dunn RL, Michalski J, et al. Quality of life and satisfaction with outcome among prostate-cancer survivors. *N Engl J Med* 2008; 20: 1250-61.
 - 8) <http://www.cancer.org/healthy/informationforhealthcareprofessionals/prostatemdcliniciansinformationsource/helpingpatientsmakeadecisionsaboutscreening/index>. Assessed 12/3/2016.
 - 9) <https://www.uspreventiveservicestaskforce.org/Page/Document/UpdateSummaryFinal/prostate-cancer-screening>. Assessed 12/3/2016.
 - 10) McCammon KA, Kolm P, Main B, and Schellhammer PF. Comparative quality-of-life analysis after radical prostatectomy or external beam radiation for localized prostate cancer. *Urology* 1999; 54: 509-516.
 - 11) Litwin MS, Hays RD, Fink A, et al. The UCLA Prostate Cancer Index: development, reliability, and validity of a health-related quality of life measure. *Med Care* 1998; 36: 1002-1012.
 - 12) Wei JT, Dunn RL, Litwin MS, Sandler HM, Sanda MG. Development and validation of the expanded prostate cancer index composite (EPIC) for comprehensive assessment of health-related quality of life in men with prostate cancer. *Urology* 2000; 56: 899-905.
 - 13) Wei JT, Dunn RL, Sandler HM, et al. Comprehensive comparison of health-related quality of life after contemporary therapies for localized prostate cancer. *J Clin Oncol* 2002; 20: 557-566.
 - 14) Frank SJ, Pisters LL, Davis J, Lee AK, Bassett R, Kuban DA. An assessment of quality of life following radical prostatectomy, high dose external beam radiation therapy, and brachytherapy iodine implantation as monotherapies for localized prostate cancer. *J Urol* 2007; 177: 2151-2156.
 - 15) Malcolm JB, Fabrizio MD, Barone BB, et al. Quality of life after open or robotic prostatectomy, cryoablation or brachytherapy for localized prostate cancer. *J Urol* 2010; 183: 1822-1829.
 - 16) Skolarus TA, Dunn RL, Sanda MG, et al. Minimally important differences for the Expanded Prostate Cancer Index Composite Short Form. *Urology* 2015; 85: 101-105.
 - 17) Willis DL, Gonzalvo ML, Brotzman M, Feng Z, Su LM. Comparison of outcomes between pure laparoscopic vs robot-assisted laparoscopic radical prostatectomy: a study of comparative effectiveness based upon validated quality of life outcomes. *BJU Int* 2012; 109: 898-905.
 - 18) Alemozaffar M, Sanda M, Yecies D, Mucci LA, Stampfer MJ, Kenfield SA. Benchmarks for operative outcomes of robotic and open radical prostatectomy: results from the Health Professionals Follow-up Study. *Eur Urol* 2015; 67: 432-438.
 - 19) Stolzenburg JU, Rabenalt R, Do M, Horn LC, Liatsikos EN. Modular training for residents with no prior experience with open pelvic surgery in endoscopic extraperitoneal radical prostatectomy. *Eur Urol* 2006; **49**:491-8.
 - 20) Oelrich TM. The urethral sphincter muscle in the male. *Am J Anat* 1980; **158**:229-46.
 - 21) Myers RP, Cheville JC, Pawlina W. Making anatomic terminology of the prostate and contiguous structures clinically useful: historical review and suggestions for revision in the 21st century. *Clin Anat* 2010; **23**:18-29.
 - 22) Walz J, Burnett AL, Costello AJ, et al. A critical analysis of the current knowledge of surgical anatomy related to optimization of cancer control and preservation of continence and erection in candidates for radical prostatectomy. *Eur Urol* 2010; **57**:179-92.

- Accepted Article
- 23) Myers RP, Cahill DR, Devine RM, King BF. Anatomy of radical prostatectomy as defined by magnetic resonance imaging. *J Urol* 1998; **159**:2148-58.
 - 24) Myers RP. Detrusor apron, associated vascular plexus, and avascular plane: relevance to radical retropubic prostatectomy--anatomic and surgical commentary. *Urology* 2002; **59**:472-9.
 - 25) Patel VR, Shah KK, Thaly RK, Lavery H. Robotic-assisted laparoscopic radical prostatectomy: The Ohio State University technique. *J Robotic Surg* 2007; **1**:51-9.
 - 26) Patel VR, Coelho RF, Palmer KJ, Rocco B. Periurethral suspension stitch during robot-assisted laparoscopic radical prostatectomy: description of the technique and continence outcomes. *Eur Urol* 2009; **56**:472-8.
 - 27) Cristini C, Di Pierro GB, Leonardo C, De Nunzio C, Franco G. Safe digital isolation of the santorini plexus during radical retropubic prostatectomy. *BMC Urol* 2013;**13**:13.
 - 28) Tufek I, Argun B, Atug F, et al. The use of a laparoscopic bulldog clamp to control the dorsal vein complex during robot-assisted radical prostatectomy: a novel technique. *J Endourol* 2013; **27**:29-33.
 - 29) Beyer B, Schlomm T, Tennstedt P, et al. A feasible and time-efficient adaptation of NeuroSAFE for da Vinci robot-assisted radical prostatectomy. *Eur Urol* 2014; **66**:138-44.
 - 30) Lei Y, Alemozaffar M, Williams SB, et al. Athermal division and selective suture ligation of the dorsal vein complex during robot-assisted laparoscopic radical prostatectomy: description of technique and outcomes. *Eur Urol* 2011; **59**:235-43.
 - 31) Lee SE, Byun SS, Lee HJ, et al. Impact of variations in prostatic apex shape on early recovery of urinary continence after radical retropubic prostatectomy. *Urology* 2006; **68**:137-41.
 - 32) Tewari AK, Srivastava A, Mudaliar K, et al. Anatomical retro-apical technique of synchronous (posterior and anterior) urethral transection: a novel approach for ameliorating apical margin positivity during robotic radical prostatectomy. *BJU Int* 2010; **106**:1364-73.
 - 33) Buckley BS, Lapitan MC, Glazener CM, Group MT. The effect of urinary incontinence on health utility and health-related quality of life in men following prostate surgery. *Neurourol Urodyn* 2012; **31**:465-9.
 - 34) Schlomm T, Tennstedt P, Huxhold C, et al. Neurovascular structure-adjacent frozen-section examination (NeuroSAFE) increases nerve-sparing frequency and reduces positive surgical margins in open and robot-assisted laparoscopic radical prostatectomy: experience after 11,069 consecutive patients. *Eur Urol* 2012; **62**:333-40.
 - 35) Rocco F, Carmignani L, Acquati P, et al. Restoration of posterior aspect of rhabdosphincter shortens continence time after radical retropubic prostatectomy. *J Urol* 2006; **175**:2201-6.
 - 36) Rocco B, Gregori A, Stener S, et al. Posterior reconstruction of the rhabdosphincter allows a rapid recovery of continence after transperitoneal videolaparoscopic radical prostatectomy. *Eur Urol* 2007; **51**:996-1003.
 - 37) Coughlin G, Dangle PP, Patil NN, et al. Surgery Illustrated--focus on details. Modified posterior reconstruction of the rhabdosphincter: application to robotic-assisted laparoscopic prostatectomy. *BJU Int* 2008; **102**:1482-5.
 - 38) Coelho RF, Chauhan S, Orvieto MA, et al. Influence of modified posterior reconstruction of the rhabdosphincter on early recovery of continence and anastomotic leakage rates after robot-assisted radical prostatectomy. *Eur Urol* 2011; **59**:72-80.
 - 39) Rocco B, Cozzi G, Spinelli MG, et al. Posterior musculofascial reconstruction after radical prostatectomy: a systematic review of the literature. *Eur Urol* 2012; **62**:779-90.

- 40) Montorsi F, Wilson TG, Rosen RC, et al. Best practices in robot-assisted radical prostatectomy: recommendations of the Pasadena Consensus Panel. *Eur Urol* 2012; **62**:368-81.
- 41) Ficarra V, Wiklund PN, Rochat CH, et al. The European Association of Urology Robotic Urology Section (ERUS) survey of robot-assisted radical prostatectomy (RARP). *BJU Int* 2013; **111**:596-603.
- 42) Walsh PC, Marschke P, Ricker D, Burnett AL. Patient-reported urinary continence and sexual function after anatomic radical prostatectomy. *Urology* 2000; **55**:58–61.
- 43) Kundu SD, Roehl KA, Eggener SE, Antenor JAV, Han M, Catalona WJ. Potency, continence and complications in 3,477 consecutive radical retropubic prostatectomies. *J Urol* 2004; **172**:2227–31.
- 44) Levinson AW, Pavlovich CP, Ward NT, Link RE, Mettee LZ, Su LM. Association of surgeon subjective characterization of nerve sparing quality with potency following laparoscopic radical prostatectomy. *J Urol* 2008; **179**:1510–4.
- 45) Strasser H, Klima G, Poisel S, Horninger W, Bartsch G. Anatomy and innervation of the rhabdosphincter of the male urethra. *Prostate* 1996; **28**:24–31.
- 46) Akita K, Sakamoto H, Sato T. Origins and courses of the nervous branches to the male urethral sphincter. *Surg Radiol Anat* 2003; **25**:387–92.
- 47) Takenaka A, Tewari A, Hara R, Leung RA, Kurokawa K, Murakami G, et al. Pelvic autonomic nerve mapping around the prostate by intraoperative electrical stimulation with simultaneous measurement of intracavernous and intraurethral pressure. *J Urol* 2007; **177**:225–229.
- 48) Catarin MVG, Manzano GM, Nóbrega JAM, Almeida FG, Srougi M, Bruschini H. The role of membranous urethral afferent autonomic innervation in the continence mechanism after nerve sparing radical prostatectomy: a clinical and prospective study. *J Urol* 2008; **180**:2527–2531.
- 49) John H, Suter S, Hauri D. Effect of radical prostatectomy on urethral blood flow. *Urology* 2002; **59**:566–569.
- 50) Nielsen ME, Schaeffer EM, Marschke P, Walsh PC. High anterior release of the levator fascia improves sexual function following open radical retropubic prostatectomy. *J Urol* 2008 **180**:2557–2564.
- 51) Kaul S, Savera A, Badani K, Fumo M, Bhandari A, Menon M. Functional outcomes and oncological efficacy of Vattikuti Institute prostatectomy with Veil of Aphrodite nerve-sparing: an analysis of 154 consecutive patients. *BJU Int* 2006; **97**:467–472.
- 52) Reeves F, Preece P, Kapoor J, Everaerts W, Murphy DG, Corcoran NM, et al. Preservation of the Neurovascular Bundles Is Associated with Improved Time to Continence After Radical Prostatectomy But Not Long-term Continence Rates: Results of a Systematic Review and Meta-analysis. *Eur Urol* 2015; **68**:692–704.
- 53) Marien TP, Lepor H. Does a nerve-sparing technique or potency affect continence after open radical retropubic prostatectomy? *BJU Int* 2008; **102**:1581–1584.
- 54) Burkhard FC, Kessler TM, Fleischmann A, Thalmann GN, Schumacher M, Studer UE. Nerve sparing open radical retropubic prostatectomy--does it have an impact on urinary continence? *J Urol* 2006 **176**:189–95.
- 55) Eastham JA, Kattan MW, Rogers E, Goad JR, Ohori M, Boone TB, et al. Risk factors for urinary incontinence after radical prostatectomy. *J Urol* 1996; **156**:1707–1713.
- 56) Sacco E, Prayer-Galetti T, Pinto F, Fracalanza S, Betto G, Pagano F, et al. Urinary incontinence after radical prostatectomy: incidence by definition, risk factors and temporal trend in a large series with a long-term follow-up. *BJU Int* 2006; **97**:1234–1241.
- 57) Suardi N, Moschini M, Gallina A, Gandaglia G, Abdollah F, Capitanio U, et al. Nerve-sparing approach during radical prostatectomy is strongly associated with the rate of postoperative urinary continence recovery. *BJU Int*. 2013; **111**:717–22.
- 58) Köhler N, Friedrich M, Gansera L, Holze S, Thiel R, Roth S, et al. Psychological distress and adjustment to disease in patients before and after radical prostatectomy. Results of a prospective multi-centre study. *Eur J Cancer Care (Engl)* 2014; **23**:795–802.
- 59) Quinlan DM, Epstein JI, Carter BS, Walsh PC. Sexual function following radical prostatectomy: influence of preservation of neurovascular bundles. *J Urol* 1991; **145**:998–1002.

- Accepted Article
- 60) Tewari AK, Srivastava A, Huang MW, Robinson BD, Shevchuk MM, Durand M, et al. Anatomical grades of nerve sparing: a risk-stratified approach to neural-hammock sparing during robot-assisted radical prostatectomy (RARP). *BJU Int* 2011; 108:984–92.
 - 61) Schatloff O, Chauhan S, Sivaraman A, Kameh D, Palmer KJ, Patel VR. Anatomic grading of nerve sparing during robot-assisted radical prostatectomy. *Eur Urol* 2012; 61:796–802.
 - 62) Moskovic DJ, Alphs H, Nelson CJ, Rabbani F, Eastham J, Touijer K, et al. Subjective characterization of nerve sparing predicts recovery of erectile function after radical prostatectomy: defining the utility of a nerve sparing grading system. *J Sexual Med* 2011; 8:255–60.
 - 63) Srivastava A, Chopra S, Pham A, Sooriakumaran P, Durand M, Chughtai B, et al. Effect of a risk-stratified grade of nerve-sparing technique on early return of continence after robot-assisted laparoscopic radical prostatectomy. *Eur Urol* 2013; 63:438–44.
 - 64) Kaye DR, Hyndman ME, Segal RL, Mettee LZ, Trock BJ, Feng Z, et al. Urinary outcomes are significantly affected by nerve sparing quality during radical prostatectomy. *Urology* 2013; 82:1348–53.
 - 65) Stolzenburg J-U, Kallidonis P, Do M, Dietel A, Hafner T, Rabenalt R, et al. A comparison of outcomes for interfascial and intrafascial nerve-sparing radical prostatectomy. *Urology* 2010; 76:743–748.
 - 66) Khoder WY, Waidelich R, Seitz M, Becker AJ, Buchner A, Tritschler S, et al. Do we need the nerve sparing radical prostatectomy techniques (intrafascial vs. interfascial) in men with erectile dysfunction? Results of a single-centre study. *World J Urol* 2015; 33:301–307.
 - 67) Takenaka A, Soga H, Sakai I, Nakano Y, Miyake H, Tanaka K, et al. Influence of nerve-sparing procedure on early recovery of urinary continence after laparoscopic radical prostatectomy. *J Endourol* 2009; 23:1115–1119.
 - 68) Ko YH, Coelho RF, Chauhan S, Sivaraman A, Schatloff O, Cheon J, et al. Factors affecting return of continence 3 months after robot-assisted radical prostatectomy: analysis from a large, prospective data by a single surgeon. *J Urol* 2012; 187:190–194.
 - 69) Lim SK, Kim KH, Shin TY, et al. Retzius-sparing robot-assisted laparoscopic radical prostatectomy: combining the best of the retropubic and perineal approaches.
 - 70) Galfano A, Di Trapani D, Sozzi F, et al. Beyond the learning curve of the Retzius-sparing approach for robot-assisted laparoscopic radical prostatectomy: oncologic and functional results of the first 200 patients with ≥ 1 year follow-up. *Eur Urol* 2013; 64: 974-80.
 - 71) Menon M. Presented at the European Robotic Urology Society, Milan, Italy, September, 2016.
 - 72) Bessede T, Sooriakumaran P, Takenaka A, Tewari A. Neural supply of the male urethral sphincter: comprehensive anatomical review and implications for continence recovery after radical prostatectomy. *World J Urol* 2016; Aug 2 Epub ahead of print

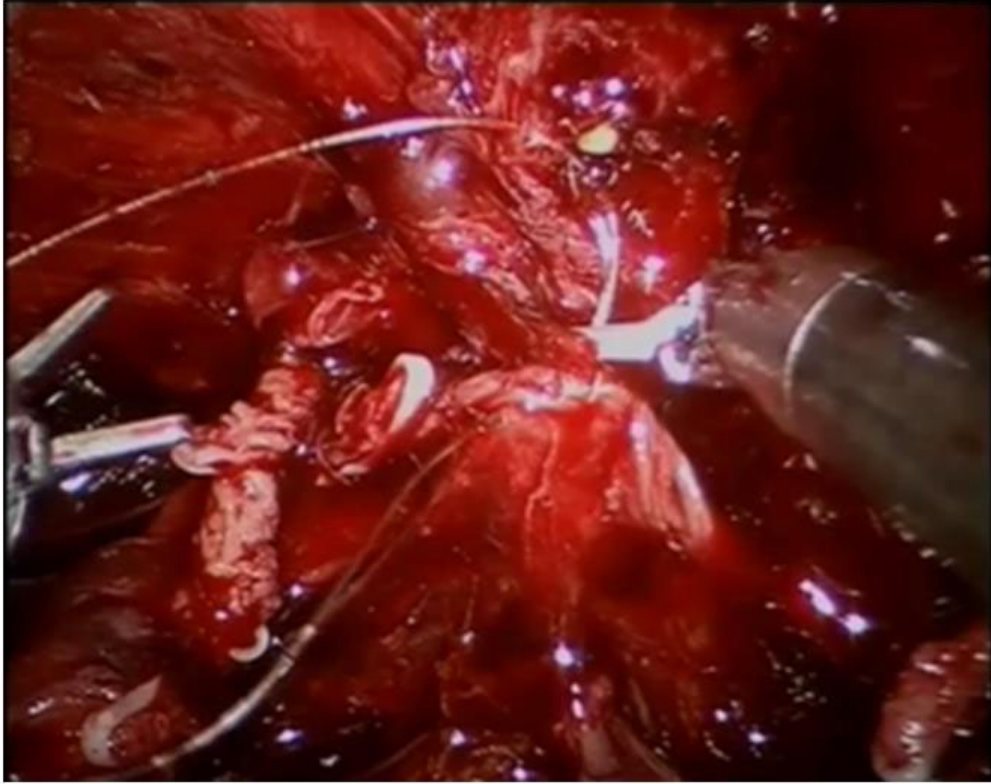


Figure. 1. First layer of posterior reconstruction. The free edge of the remaining Denonvillier's fascia is approximated to the posterior aspect of the rhabdosphincter reconstruction

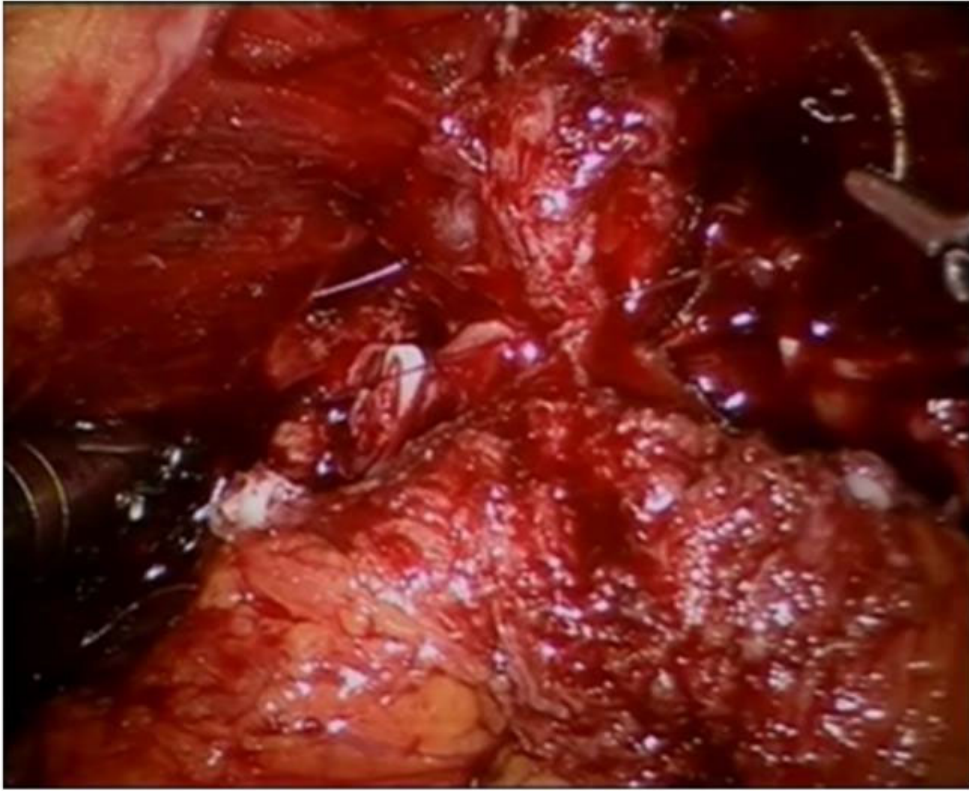


Figure 2. Second layer of posterior reconstruction. The posterior lip of the bladder neck and vesicoprostatic muscle are sutured to the posterior urethral edge reconstruction.

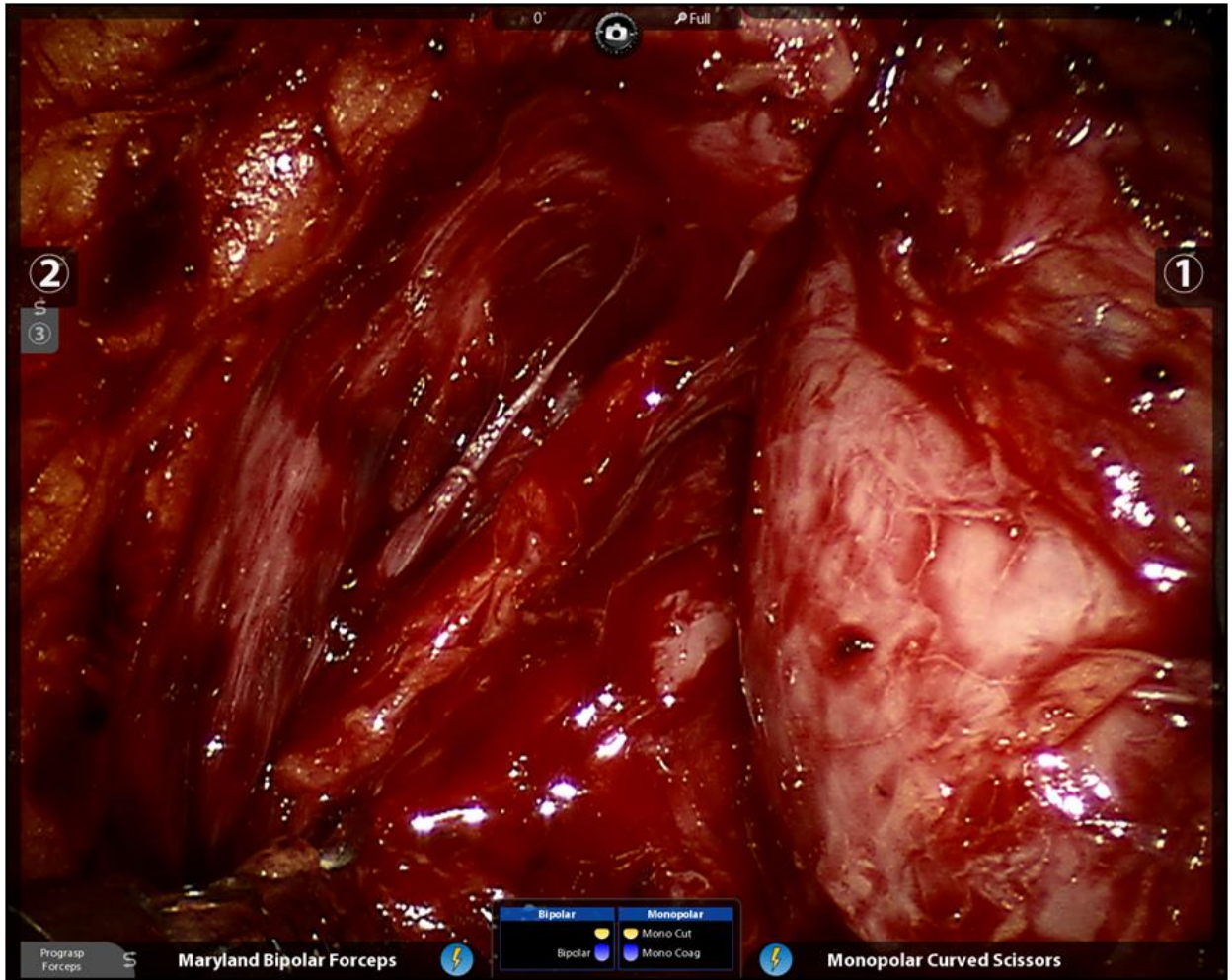

Figure 3a. These intraoperative images of robotic RP (surgeon--Pavlovich) demonstrate the left neurovascular bundle being spared to varying degrees during interfascial dissection. Image A. demonstrates nerve sparing grade 4 on a 0-4 scale with 4 being the best [61, 64](the bundle is wide, high, and associated with a significant amount of associated tissue, without break from base to apex). Image B. depicts nerve sparing to a lesser extent, graded a 3 on the same 0-4 scale (the bundle is without obvious defect but is much thinner and has less surrounding vascular and supportive tissue remaining).

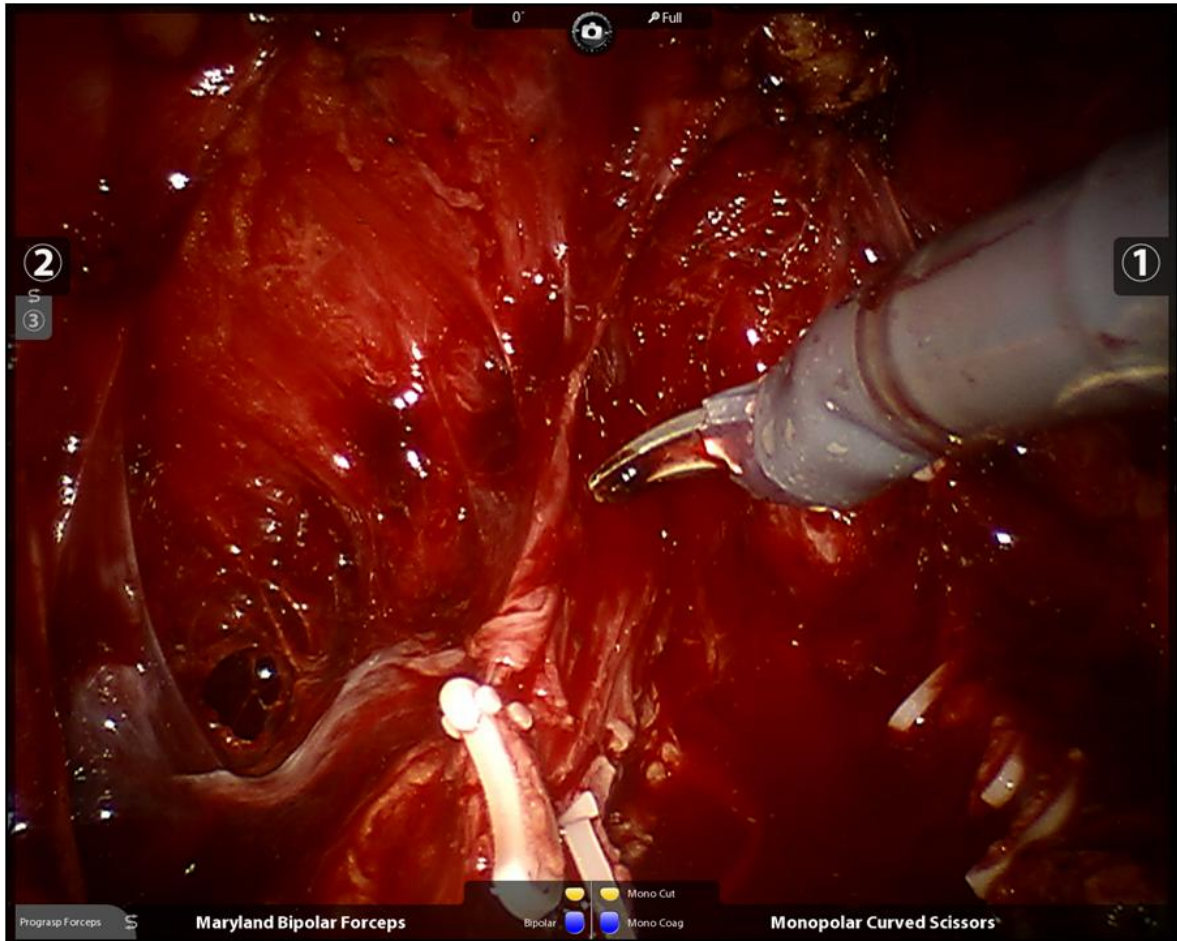


Figure 3b. These intraoperative images of robotic RP (surgeon--Pavlovich) demonstrate the left neurovascular bundle being spared to varying degrees during interfascial dissection. Image A. demonstrates nerve sparing grade 4 on a 0-4 scale with 4 being the best [61, 64] (the bundle is wide, high, and associated with a significant amount of associated tissue, without break from base to apex). Image B. depicts nerve sparing to a lesser extent, graded a 3 on the same 0-4 scale (the bundle is without obvious defect but is much thinner and has less surrounding vascular and supportive tissue remaining).

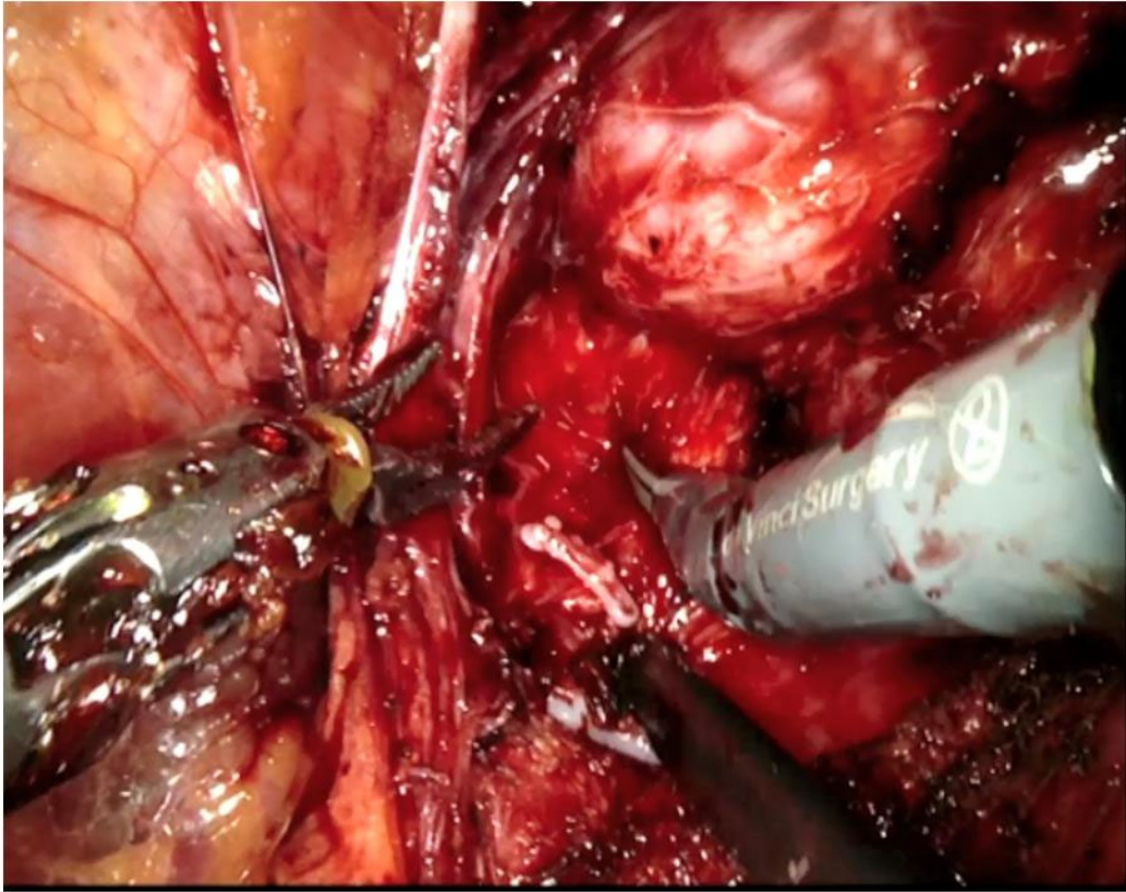


Figure 4—Confirmatory images. Robotic RP (Surgeon—Davis) for favorable risk disease. The high anterior release is completed, as retracted by the left hand grasper. The posterior lateral plane is now being developed. This demonstrates another surgeon's technique for table 1: bilateral excellent nerve sparing or grade 4).

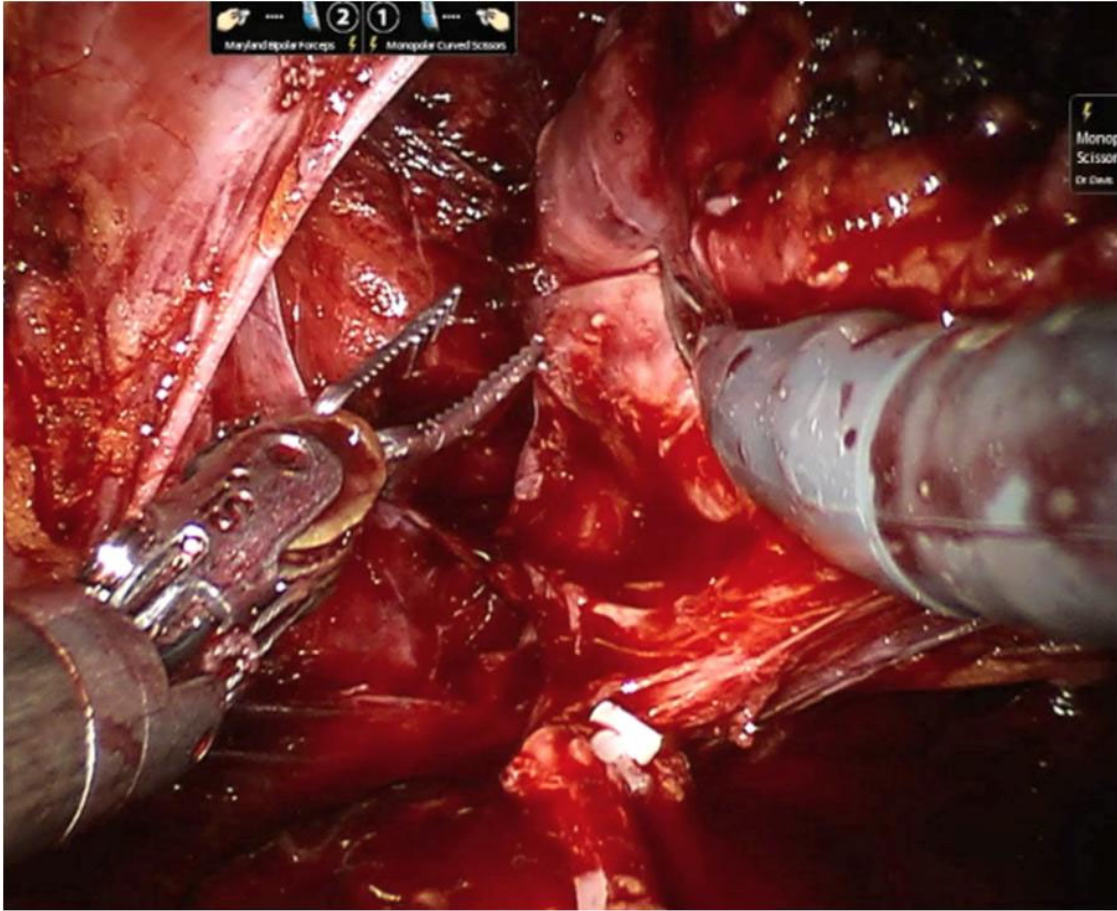


Figure 5a. Confirmatory image—high risk disease. Robotic RP (surgeon-Davis) demonstrating intended grade 3—nerve sparing but low release with no intent to spare anterior tissue. Image 5a—early nerve release step. Image 5b—nerve release turning to the apex.

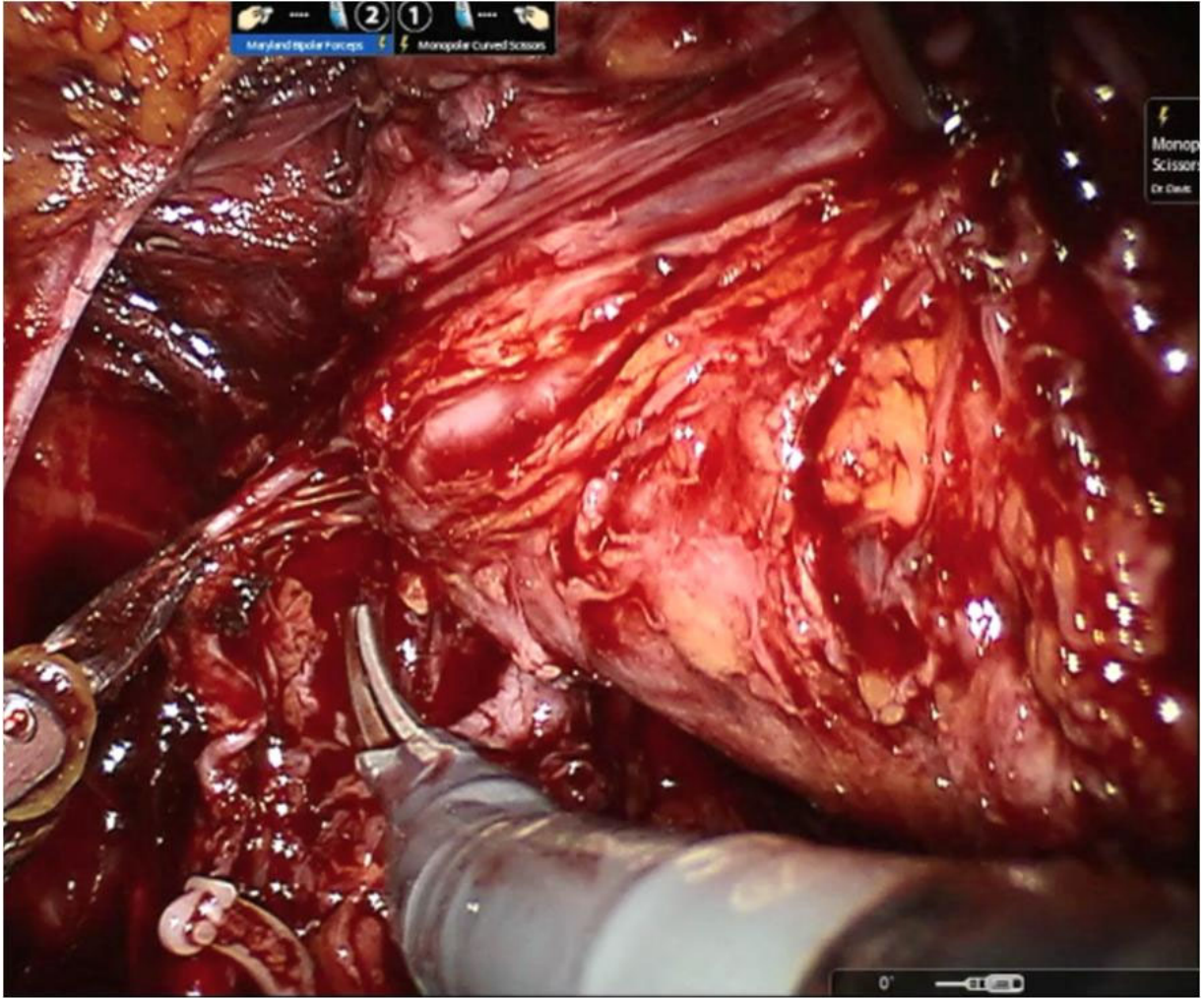


Figure 5b. Confirmatory image—high risk disease. Robotic RP (surgeon-Davis) demonstrating intended grade 3— nerve sparing but low release with no intent to spare anterior tissue. Image 5a—early nerve release step. Image 5b—nerve release turning to the apex.

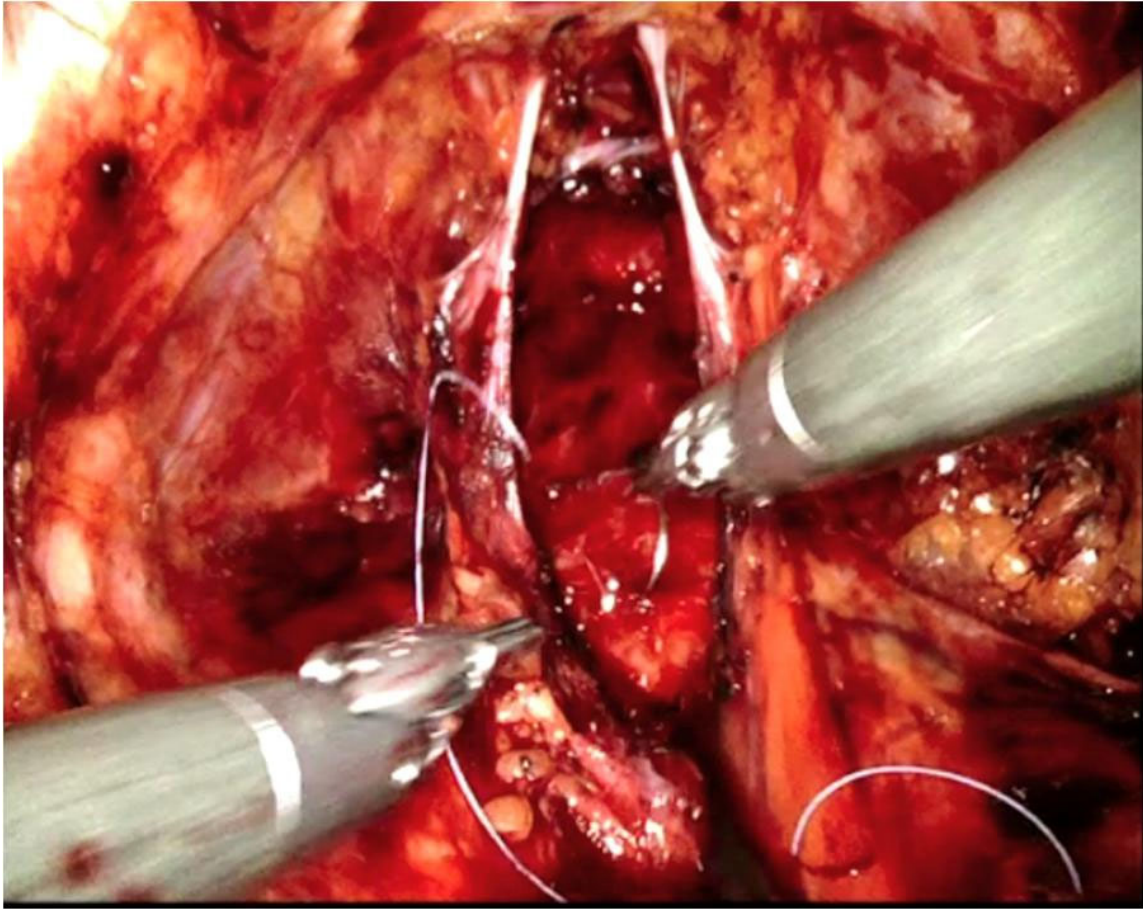


Figure 6a. Confirmatory images post resection—robotic RP (surgeon—Davis). In this same case for figure 4, the appearance is demonstrated of high anterior release. In image 6b—the same high risk case with low release. While standard, low release has the appearance often described as “train tracks” post resection, the high release looks more like a bowl.

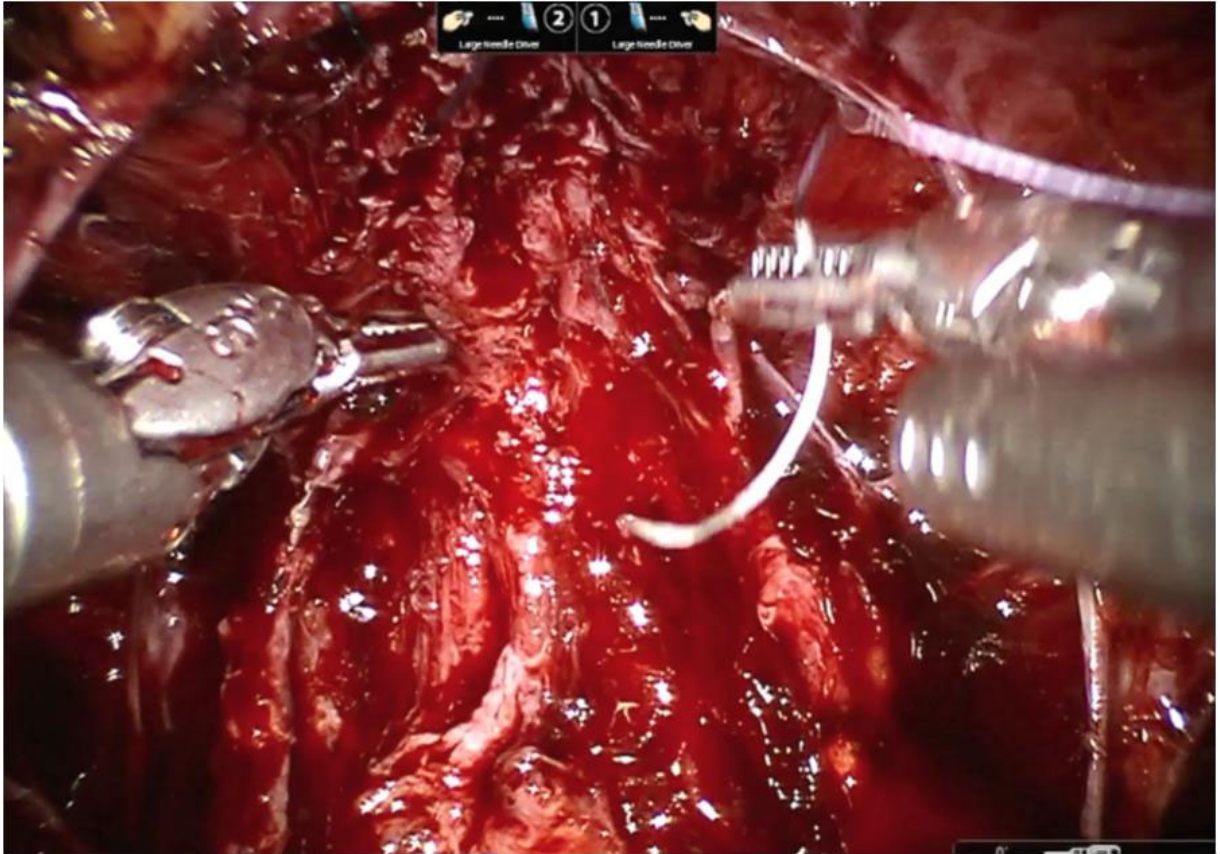


Figure 6a. Confirmatory images post resection—robotic RP (surgeon—Davis). In this same case for figure 4, the appearance is demonstrated of high anterior release. In image 6b—the same high risk case with low release. While standard, low release has the appearance often described as “train tracks” post resection, the high release looks more like a bowl.

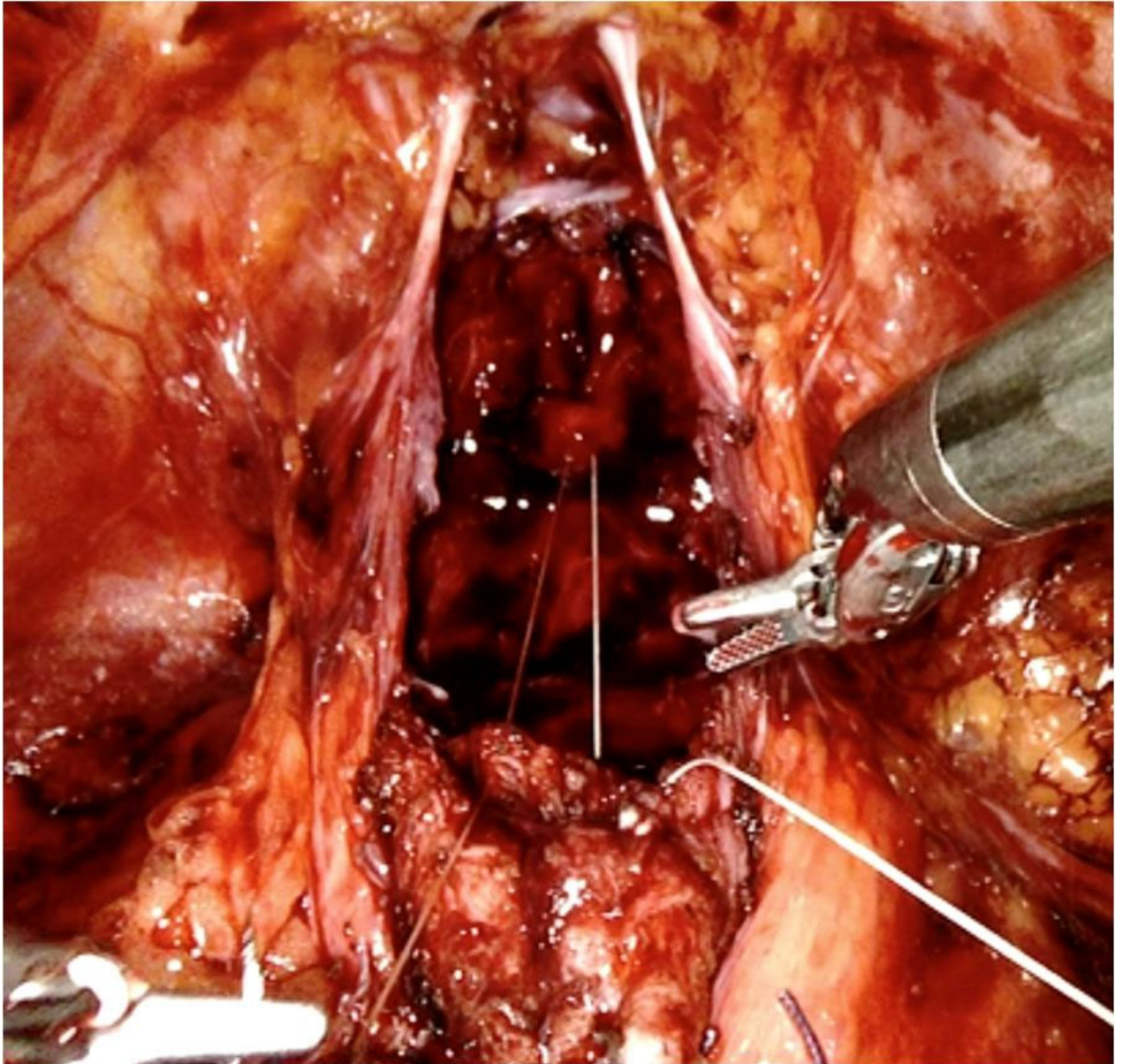


Figure 7a—Rocco confirmation. Robotic RP from the favorable risk case (surgeon—Davis) shows the second step approximating the longitudinal layer under the bladder with the posterior rhabdosphincter. Image a shows a 3-0 Vicryl configure as a U-stitch, such that when tied (image b) the knot buries into the tissue to hold tension and allow easy approximation in < 2 minutes.

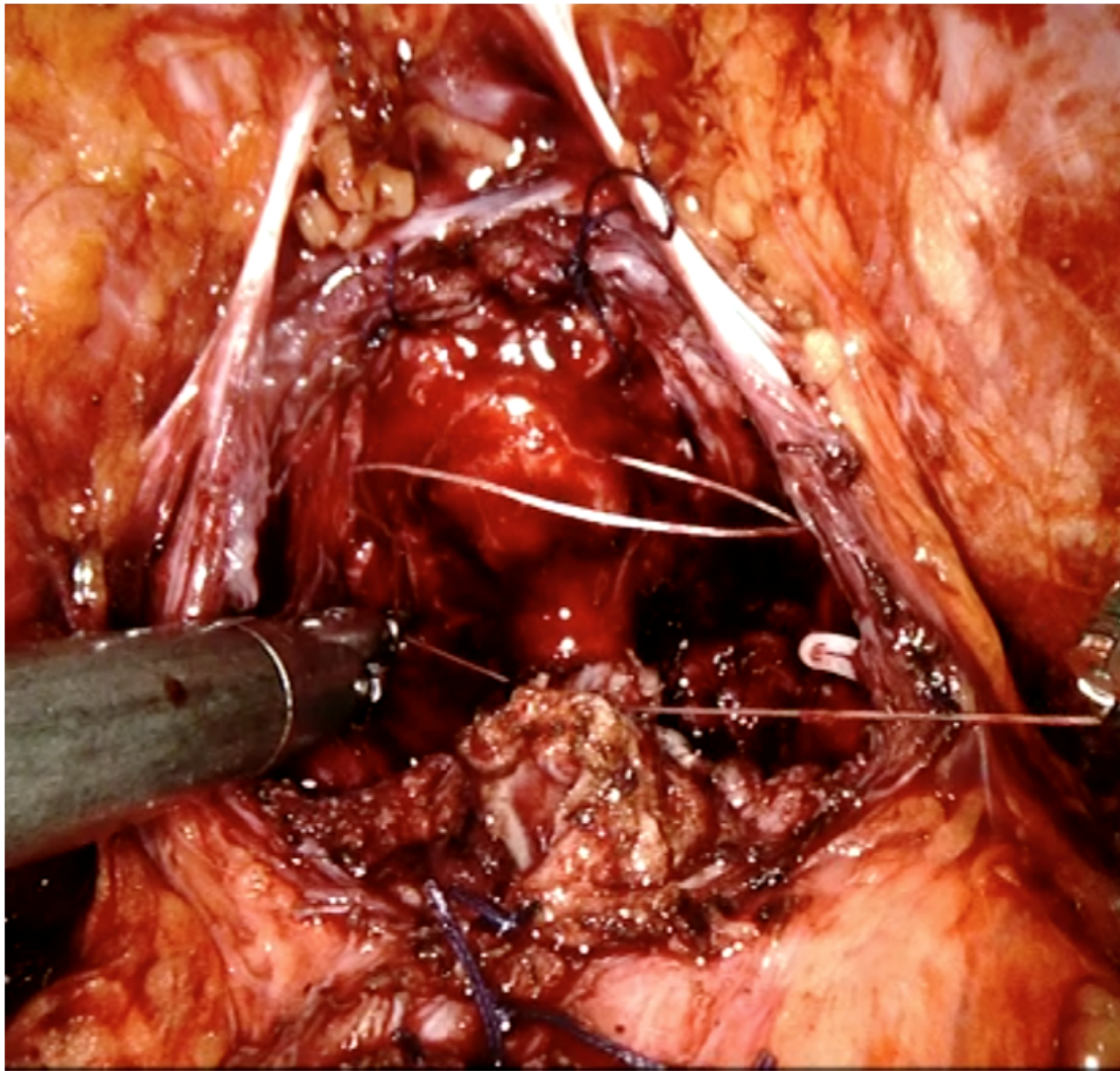


Figure 7b—Rocco confirmation. Robotic RP from the favorable risk case (surgeon—Davis) shows the second step approximating the longitudinal layer under the bladder with the posterior rhabdosphincter. Image a shows a 3-0 Vicryl configure as a U-stitch, such that when tied (image b) the knot buries into the tissue to hold tension and allow easy approximation in < 2 minutes.